

## Split Cord Malformation - A Diagnosis Missed

Nimrah Mairaj<sup>1</sup>, Abdul Ali<sup>2</sup>, Zainab Juzer<sup>3</sup>, Sadiq Mirza<sup>4</sup>, Sina Aziz<sup>5</sup>

### Abstract

In this report, we describe the case of an 8 year old female child who presented with complaints of swelling in sacral region since birth and left leg weakness since 2 years of age. She presented with left clubbed foot to an orthopaedic surgeon and was treated at 1 year of age with serial plasters. The child was presented for club foot, rather than identifying the cause of deformity. When child was presented to our tertiary care hospital her workup was done and an incidental finding of split cord malformation on Magnetic Resonance Imaging (MRI) and Computed Tomography (CT) myelogram was revealed along with left gluteal sebaceous cyst. The child underwent surgery and tethering of cord by the fibrous septa was relieved along with excision of left gluteal sebaceous cyst. The post-operative course was uneventful. Spinal cord malformations usually present with number of presentations for example hypertrichosis, lipoma, dermal sinus or tail. Therefore, a thorough examination can result in early diagnosis of the malformation and the complications can be prevented. In our case hypertrichosis at the back was missed, prior to child being referred to us. Hence, this case is being reported as a diagnosis missed of split cord malformation due to lack of complete head to toe evaluation of child by a subspecialty expert.

**Keywords:** Orthopedic surgeons, Magnetic Resonance Imaging, spinal cord, cyst, diagnosis.

**Citation:** Mairaj N, Ali, A, Juzer Z, Mirza S, Aziz S. Split Cord Malformation - A Diagnosis Missed [Online]. *Annals ASH KM&DC* 2017;22:81-4. Available from: [www.annals-ashkmdc.org](http://www.annals-ashkmdc.org).

(ASH & KMDC 22(3):228;2017)

### Introduction

Split cord malformation is a rare form of occult dysraphism in which the spinal cord is divided into two halves<sup>1</sup>. There are two types: in type 1 there are two spinal cords, each in its own Dural tube and separated by a spicule of bone and cartilage. In type 2 the spinal cords are enclosed in a single dural sac with a fibrous septum between the two spinal segments. In both types patient may present with subtle neurological signs such as unilateral calf atrophy, a high arch to one or both feet early in

life but they are neurologically normal<sup>1</sup>. Signs and symptoms of tethered cord are present; later clinical manifestations are progressive loss of bowel and bladder function, sensory and motor difficulties in lower extremities and back pain. About 90% of patients with split cord malformation have cutaneous manifestations i.e. hypertrichosis, lipoma, dermal sinus or tail. Local data regarding split cord malformation is lacking, hence, we present a case of type 2 split cord malformation, which came with left club foot and left leg weakness and a swelling at the back. During investigation tufts of hair were also found.

### Case Report

Eight years old female child presented in neurosurgery out patient department of Abbasi Shaheed Hospital in March 2016 with complaint of swelling in the sacral region since birth and left leg weakness

<sup>1,3,4,5</sup> Department of Paediatrics, Abbasi Shaheed Hospital & Karachi Medical & Dental College

<sup>2</sup> Department of Neurosurgery, Abbasi Shaheed Hospital & Karachi Medical & Dental College

**Correspondence:** Dr. Nimrah Mairaj  
Department of Paediatrics, Abbasi Shaheed Hospital  
and Karachi Medical and Dental College

Email: [nimrah\\_mairaj@hotmail.com](mailto:nimrah_mairaj@hotmail.com)

Date of Submission: 11<sup>th</sup> July 2017

Date of Acceptance: 9<sup>th</sup> September 2017

since 2 years of her age. No history of numbness or loss of sensation in lower limbs, there was no urinary or faecal incontinence, no history of trauma, headache or fits. There was history of left club foot at birth, for which serial plasters were applied from 6 months of age to 1 year of age. Birth and family history was unremarkable and she was the first product of non-consanguineous marriage.

On clinical examination in a hospital, Glasgow Coma Score was 15/15, gait was spastic type with increased tone in both lower limbs, power 5/5 and brisk reflexes, planters were down going. Sensations were intact. Talipesqueineous deformity of left foot was present. Examination of swelling at the sacral region revealed 2cm soft non-tender swelling with a dermal sinus just above the swelling (Fig. 1).

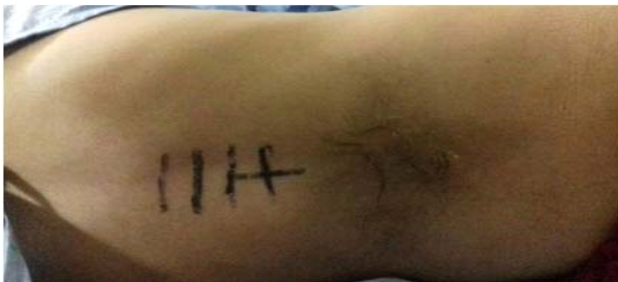

Fig. 1. Swelling at the sacral region with dermal sinus above the swelling

Magnetic Resonance Imaging (MRI) of lumbar spine was carried out which revealed the presence of subcutaneous cystic lesion near the tip of coccyx on left side.

Ultrasound of the lesion was advised where the incidental finding of tuft of hairs at the back was found. Then workup for spinal dyraphism was done for which Computed Tomography scan of dorsal and lumbosacral spine (myelogram) and MRI advised.

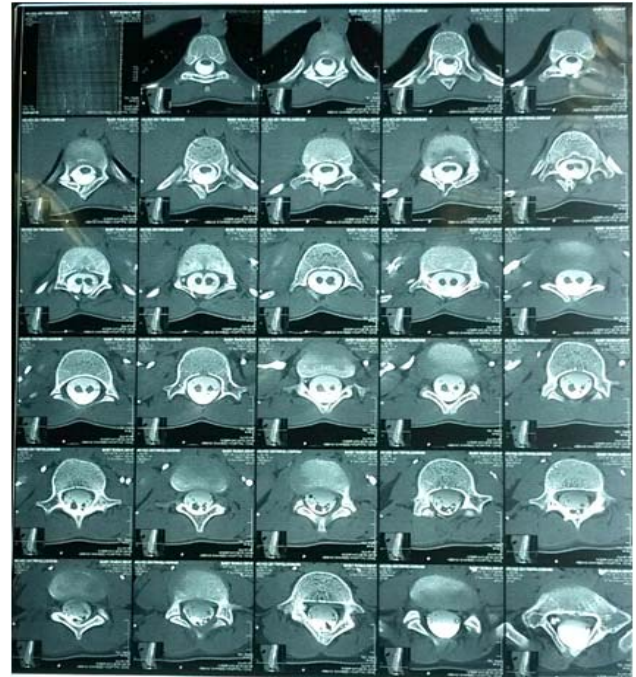

Fig. 2. CT scan of dorsal and lumbosacral spine showing duplication of the distal spinal cord

CT scans of dorsal and lumbosacral spine revealed duplication of the distal spinal cord. Fibrous septum noted between the hemi-cord at D11 level. The left hemi-cord extending down with conus medullaris at L1 level and thickening of filum terminale. The right hemi-cord extending down to the level of intervertebral disc at L4-L5 level. Filum terminale on either side joined together at L4-L5 level and tethered to posterior bony elements/lamina of L5 at left side. There was no available evidence of thickened filum terminale on CT scan or MRI of spine. There was associated Dural ectasia present. Defects seen at multiple levels involving lower dorsal and upper lumbar spine sacral segments representing spina bifida. Incidental finding of bifid collecting system was noted in the left kidney with double ureter.

On MRI of dorsal spine there was evidence of division of spinal cord in two hemi-cords at the level of D10 to L2 vertebra. Conus medullaris was noted to lie low up to the level of L4 vertebra. There was a

bony spur seeming to be arising from the body of D11 and D12 vertebra causing a bifid spinal cord.

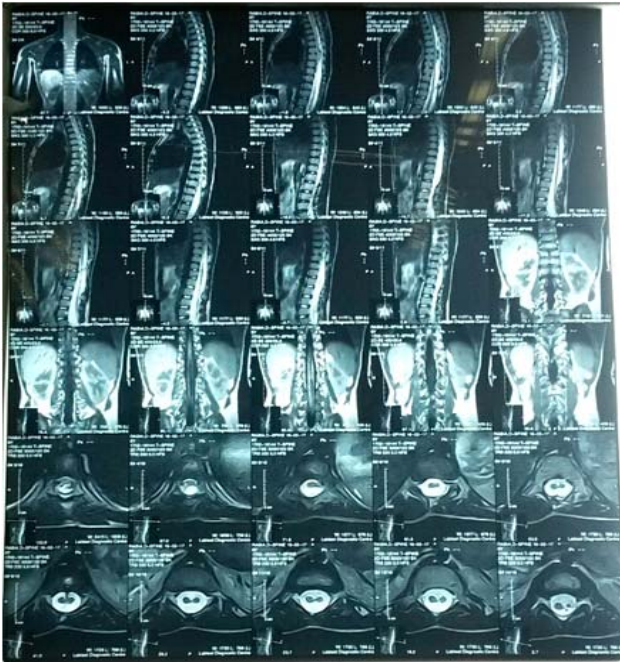


Fig. 3. MRI of dorsal spine, dorsum of spinal cord counts medularis at L4 level and bony spur from body of D11 and D12 with bifid spinal cord

Then the surgery was performed and midline skin excision given from D12 to L2 level. Spina bifida identified laminectomy of bifid spine done from D12 TO L1. Dura opened, fibrous band (septa) seen running through the double spinal cord.

The band excised completely from dorsal and ventral Dural attachment. Left gluteal sebaceous cyst was excised by a separate incision.

Patient was shifted to Paediatric Intensive Care Unit-II of Abbasi Shaheed hospital and was kept on broad spectrum antibiotics. She went through an uneventful post-operative recovery and no new neurological deficits noted and shifted to the ward after 2 days.

Opinion regarding the bifid collecting system in the left kidney with double ureter was taken and no surgical intervention was advised as the patient was not symptomatic.

Child was sent home and followed in Out Patient Department where child was clinically well.

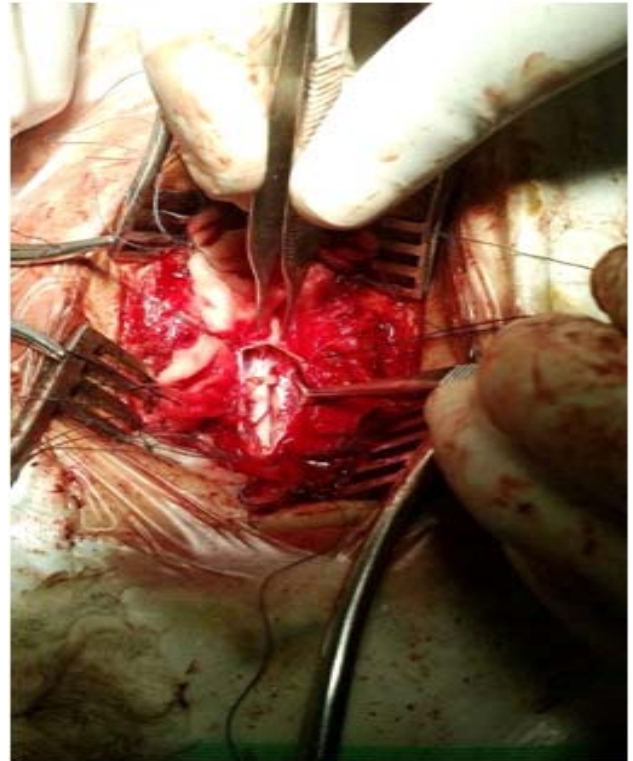


Fig. 4. Shows complete excision of band from dorsal and ventral dermal attachment

### Discussion

Spilt cord syndrome also called diastematomyelia is a rare form of spinal cord anomaly<sup>2</sup>. According to unified theory of embryogenesis all variant types of split cord malformation (SCMs) have a common embryogenetic mechanism which is formation of adhesions between ecto- and endoderm, leading to an accessory neurenteric canal around which condenses an endomesenchymal tract that bisects the developing notochord and causes formation of two hemi neural plates<sup>3</sup>. Thus the development of neurenteric canal forms basis for formation of spilt cord syndrome. SCM is divided into 2 types; in type 1 spilt cord malformation, there is two spinal cords within its own covering separated by cartilage or bone and in type 2 malformation two spinal cord are within the same covering. Our patient presented with type 2 malformations with cartilage be-



tween them. Our patient primarily presented with talipespedalis and left gluteal sebaceous cyst to medical attention. A study in India reported foot malformations in 10 out of 53 patients. It is also reported associated with hypertrichosis (13 out of 53) and dermal sinus<sup>4</sup> similar to finding of hypertrichosis in our patient which prompted further evaluation and investigation. SCMs can be asymptomatic or present with pain, gait disturbance, motor or sensory deficits, and autonomic dysfunction<sup>5</sup>. Our patient had left leg weakness for 6 years; her bowel functions were intact and there was no sensory deficit. It is more common in lower cord (50% between L1 to L3) as seen in our patient. Split cord has also been reported to present with unusual manifestations such as dorsal enteric sinus and capillary hemangioma<sup>6,7</sup>; MRI is the choice of investigation. Surgical intervention is corner stone of treatment and can be attempted in asymptomatic individuals to prevent tethering of cord. According to a two year research study most asymptomatic patients treated with surgical correction had no post-operative deterioration and improved outcomes<sup>4</sup>.

### Conclusion

A complete physical head to toe and especially neurological examination is the key to accurate and early diagnosis. Our case was unique as few cases of SCM have been reported from this part of world.

### Conflict of Interest

Authors have no conflict of interests and no grant/ funding from any organisation for this study

### References

1. Rekate H I. Nelson textbook of Pediatrics. Spinal Cord Disorder, Diastematomyelia. 20th Edition. p:2952-54..
2. Khandelwal A, Tandon V, Mahapatra AK. An unusual case of 4 level spinal dysraphism: Multiple composite type 1 and type 2 split cord malformation, dorsal myelocystocele and hydrocephalous. *J Pediatr Neurosci* 2011;6:58-61.
3. Pang D, Dias MS, Ahab-Barmada M. Split cord malformation: Part I: A unified theory of embryogenesis for double spinal cord malformations. *Neurosurgery* 1992;31:451-80.
4. Borkar SA, Mahapatra AK. Split cord malformations: A two years experience at AIIMS. *Asian J Neurosurg* 2012;7:56-60.
5. Akhtar S, Azeem A, Shamim MS, Tahir MZ. Composite split cord malformation associated with a dermal sinus tract, dermoid cyst, and epidural abscess: A case report and review of literature. *Surg Neurol Int* 2016;7:43. [DOI: 10.4103/2152-7806.180764].
6. Nanda M, Bawa M, Kanojia RP, Rao KL. Dorsal enteric sinus with spina bifida: a rare form of split notochord syndrome. *Pediatr Neurosurg* 2010;46:138-40. [DOI: 10.1159/000319398].
7. Izci Y, Gurkanlar D, Gönül E. An unusual type of split cord malformation. *J Clin Neurosci* 2007;14:383-6. [DOI: 10.1016/j.jocn.2005.12.016].

---

### Answers of QUIZ

**Q.1: (C) Pneumocephalus**

**Q.2: (C) Meningitis**

**Q.3: (C) Conservative and surgical management both.**