

# Functional Appliance Therapy Using Twin-block Appliance in Class II Division - 1 Patient - Case Report

Yahya Jaber Alshahrani

## Abstract

Functional appliance therapy is a very effective mode of treatment especially in mixed dentition. It not only corrects the dentoalveolar malocclusion as well as moulds the skeleton according to patient's functional demand. It not only corrects the overjet, overbite but may also correct transverse skeletal problems which improve patient's self-esteem, confidence and interpersonal skills. A 10 years 6 month old boy presented with the complaint of proclination of maxillary teeth. His parents were very concerned about his facial appearance especially visible upper front teeth. His profile was convex with an obtuse nasolabial angle and acute labiomental sulcus with lower lip trap habit reported. He was in late mixed dentition and had Class II Division I malocclusion with excessive overjet. After thorough history, clinical examination and investigations he was planned for the fixed orthodontic treatment along with twin block functional appliance therapy.

**Keywords:** Class II malocclusion, orthodontic appliances, maxilla

(ASH & KMDC 25(3):186;2020)

## Introduction

Functional appliances have been used for many years in the treatment of Class II malocclusions. Alteration of maxillary growth, improvement in mandibular growth and position, and change in dental and muscular relationships are the expected effects of these appliances<sup>1</sup>.

The twin block was used during growth phase of patient and works simultaneously on the skeleton of maxilla and mandibular skeleton. It was invented in 1980 by Clark. It is a patient's friendly appliance commonly used to treat underdeveloped jaws<sup>2</sup>. Functional appliance therapy is followed by comprehensive fixed-appliance therapy with or without extractions. Extraction of all first premolars is indicated primarily for dental crowding, cephalometric discrepancy, or a combination in growing Class

Department of Orthodontics, Ministry of Health, Riyadh  
Saudi Arabia

**Correspondence:** Dr. Yahya Jaber Alshahrani  
Ministry of Health, Riyadh  
Saudi Arabia

**Email:** yahyaalshahrani1979@gmail.com

**Date of Submission:** 2<sup>nd</sup> August 2020

**Date of Acceptance:** 9<sup>th</sup> November 2020

II patients<sup>3</sup>. It has been reported that the efficiency of treatment of a retrognathic mandible strongly depends on the biologic responsiveness of the condylar cartilage. It not only corrects the overjet, overbite but may also correct transverse skeletal problems which indirectly improves patient's self-esteem, confidence and interpersonal skill<sup>4</sup>. During functional appliance treatment, changes in the mandibular condyle relative to mandibular advancement highly depend on the duration of functional therapy plus the direction, amount, and types of forces used<sup>5</sup>.

This case report demonstrates the use of the twin - block appliance followed by full fixed orthodontic treatment in a skeletal Class II Division 1 patient with a retrognathic mandible, protruding maxillary anterior teeth, excessive overjet, and complete overbite. This case report will help the Orthodontists to plan and perform functional appliance therapy in patients with Class II division 1 patients.

## Case report

A 10 years 6 months old boy presented with the complaint of "my front teeth are coming forward". His parents were very concerned about his

**Table 1.** showing cephalometric value after cephalometric analysis

Variable	Pre-treatment	Post-functional	Post-treatment	Change
SNA	79°	77.5°	77°	2°
SNB	73.5°	75.5°	75°	1.5°
ANB	5.5°	2.5°	2°	3°
Upper incisor to PP	122.0°	118.0°	115.0°	7°
Lower incisor to mandibular plane	94.5°	96.5°	97°	2.5°
Inter incisal angle	122.8°	128.8°	127°	4.2°
FMA	24.4°	22.1°	20.7°	3.7°
Lower anterior face height	58 mm	58 mm	61mm	3mm
Lower to total facial height ratio	54.2%	54.7%	55 %	0.8%
Lower incisor to Apo	-2.2mm	-1.2mm	1.2mm	3mm
Lower lip to E plane	-4.0mm	-3.3 mm	-2 mm	2mm

facial appearance especially the visible upper front teeth.

This case of orthodontic malocclusion was reported and treated at the department of Orthodontics, Riyadh Elm University, Kingdom of Saudi Arabia. Treatment was started on March 2016 and ends on May 2018. Informed consent was taken from the patient. Patient has non-significant medical history and dental history of dental extractions of primary teeth. His profile was convex with obtuse nasolabial angle and acute labiomental sulcus with lower lip trap habit reported.

Intraoral examination revealed poor oral hygiene. He was in late mixed dentition. He had Class II division-I malocclusion with excessive overjet of 9mm and overbite of 8 mm which represents 100% of lower incisors overlapped by upper incisors, mandibular to maxillary midline is deviated to the left by 2 mm. On the left side, molar classification was Class II, canines were unerupted. On right side, molars have 3/4 unit Class II relationship, mild crowding, overlapped and proclined upper central incisors. There was no transverse discrepancy. However, during TMJ evaluation, he did not report any muscle pain, joint pain, or other symptoms typically associated with temporomandibular disease (Fig 1).

The panoramic radiograph showed condyles, maxillary sinuses, nasal floor and nasal septal are normal. Late mixed dentition. All permanent teeth

are present and developing normally (Fig 2). Patient's cephalometric analysis was performed by the researcher. The lateral cephalometric analysis indicated a skeletal Class II pattern SNA angle of 79°, SNB angle of 73.5°, ANB angle of 5.5° with a hypodivergent mandible (SN-MP, 21.5). Maxillary incisor teeth have proclination of 122° followed by mandibular incisor teeth had an average inclination of 93°. There was reduction of interincisal angle which decreases at 122°. Mandibular incisors to AP and lower lip to E line were in normal range (Fig 2 & Table 1).

In light of history, examination and cephalometric and OPG analysis the final diagnosis of Class II division-1 with excessive overjet was made and patient was called to discuss the treatment options. The treatment plan was divided into two stages.

Stage I of management tangled usage of functional appliance for at least 12 hours a day to minimize overjet, attain class I molar relationship and in addition retention in beginning of management. Besides, it also refines the patient's facial contour. The project of maxillary part incorporates an acrylic baseplate which shields palate and occlusal planes of maxillary first molars and second premolars. It has an inclined plane at the termination of mesial end of acrylic block. A midline screw was also incorporated. The mandibular component comprised of labial ball clasp to enhance retention by engaging ball end clasps in buccal segments. Both blocks had Adams clasps over first molars to im-

prove posterior retention. There was trail alongside maxillary and mandibular fixed appliances (0.022" slot brackets) for relaxation of crowding, detailing and finishing.

As treatment progressed aims of functional treatment phase I were achieved successfully due to patient cooperation (Fig 3). The patient was instructed to activate the midline screw twice a week and was reviewed every four weeks. This phase of treatment was completed over 9 months. Growth modification with use of functional appliance retroclined the upper incisors by 2° while the lower incisors proclined by 2°. This resulted in reduction of overjet and good Class I molar relation was achieved on both right and left side. Lower lip trap was eliminated due to favourable vertical and antero-posterior growth with the lips being competent at the end of treatment. Overall, a good static and functional occlusal result was achieved.

The second phase of treatment with the fixed appliances aimed to relieve the crowding and finish the case with upper and lower pre-adjusted edge-wise appliances (0.022" slot, with a MBT prescription) on a non-extraction basis (Figure- 4&5). There was a chance of poor periodontal state of mandibular central incisors. Although through meticulous oral hygiene maintenance and cautious monitoring it can be minimized as possible.

The duration of treatment was two years i.e. nine months functional appliance therapy, 3 months transitory period amongst functional and fixed orthodontics and 12 months fixed appliance therapy. Cephalometric super imposition tracing was performed by the researcher by superimposing the post-treatment cephalometric radiograph with pre-treatment radiograph to evaluate the outcome of treatment (Fig 6). There was correction in profile. All dental malocclusion was corrected along with vertical and transverse tooth relationships. The patient was recalled after 18-month for post treatment examination and the records showed no significant relapse, and the patient had a stable occlusion.

## Discussion

A young patient was treated using functional jaw orthopaedics with the help of twin block appliance along with fixed orthodontic therapy.

Another treatment option for this patient could be fixed appliance using intermaxillary traction class II. However, this technique decreased the chances of proper proclined mandibular incisors and corrected class I molar relationship. Although it was difficult to achieve reinforced anchorage because of mesial drifting of maxillary molars hence difficulty in attainment of desired treatment objectives<sup>6</sup>.

However, this appliance offers many benefits which involves acceptable tolerability by the patient, strong, not difficult to mend, and it is appropriate for usage in both adult and teenagers. They modify the treatment followed by fixed braces which ultimately achieved class I molar relationship. The reported demerits of appliance were that it may lead to excessively proclined mandibular anterior teeth and potential for the incorporation of posterior open bites. Most of the aims of therapy in the reported patient were successfully accomplished and reduction in overjet was attained. It dramatically improved patient's confidence, self-esteem and reduces the chances of maxillary incisor's damage which may occur due to trauma<sup>7</sup>. A modified Clark's twin block appliance was chosen for growth modification which had Adam's clasp on both upper and lower first molars for better retention<sup>8</sup>. The midline screw was rotated at the rate of 0.25 mm expansion per revolution. Growth modification favoured the antero-posterior and vertical skeletal growth thereby improving the skeletal Class II pattern, and providing dentoalveolar changes which accurate molar relationship along with improvement in overjet and overbite. The ANB was reduced by 2.5°, indicating favourable growth of mandible which resulted in reduction of the antero-posterior skeletal discrepancy. The upper incisors were retroclined but the increased palatal root torque in MBT bracket (-17°) helps counteract post functional incisor retroclination. The lower incisors got slightly proclined but still within the normal value.

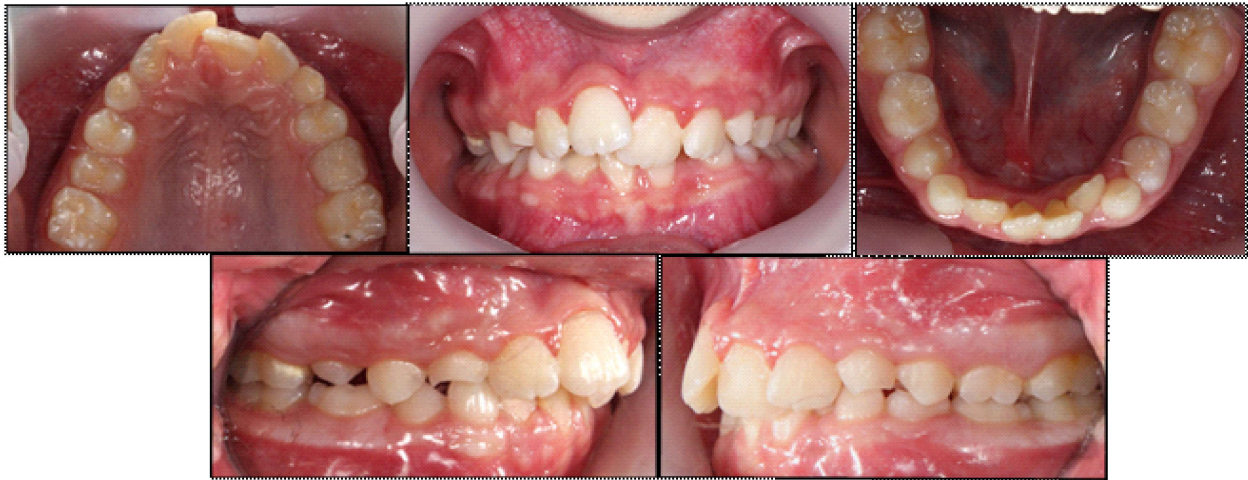

Fig 1. Showing pre-treatment intraoral views of patient

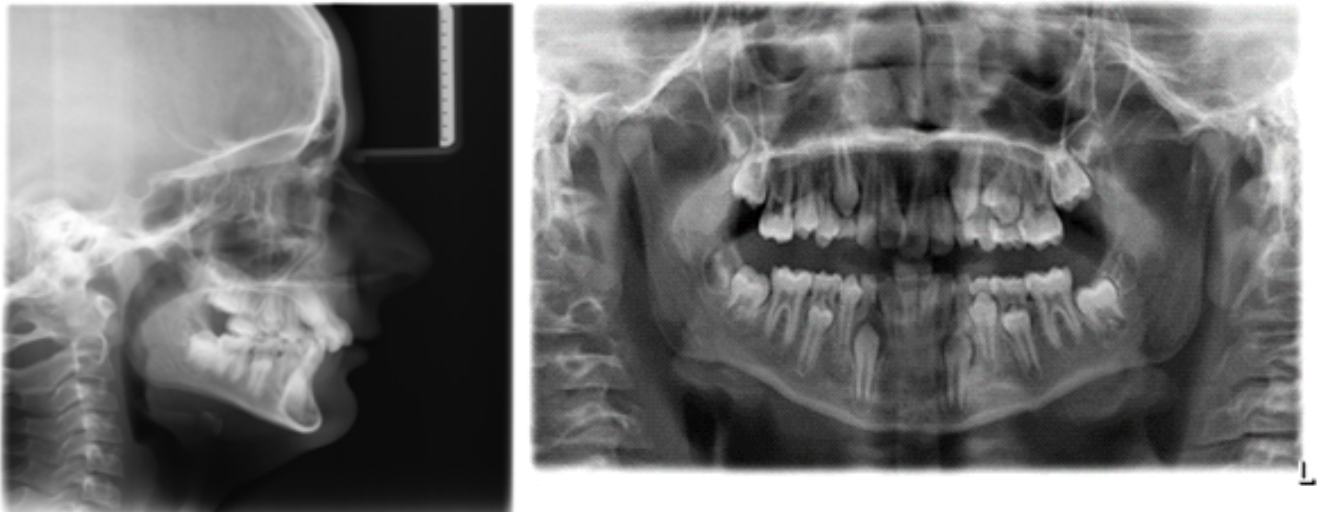


Fig 2. Pre-treatment radiographs: A, lateral cephalogram; B, panoramic radiograph

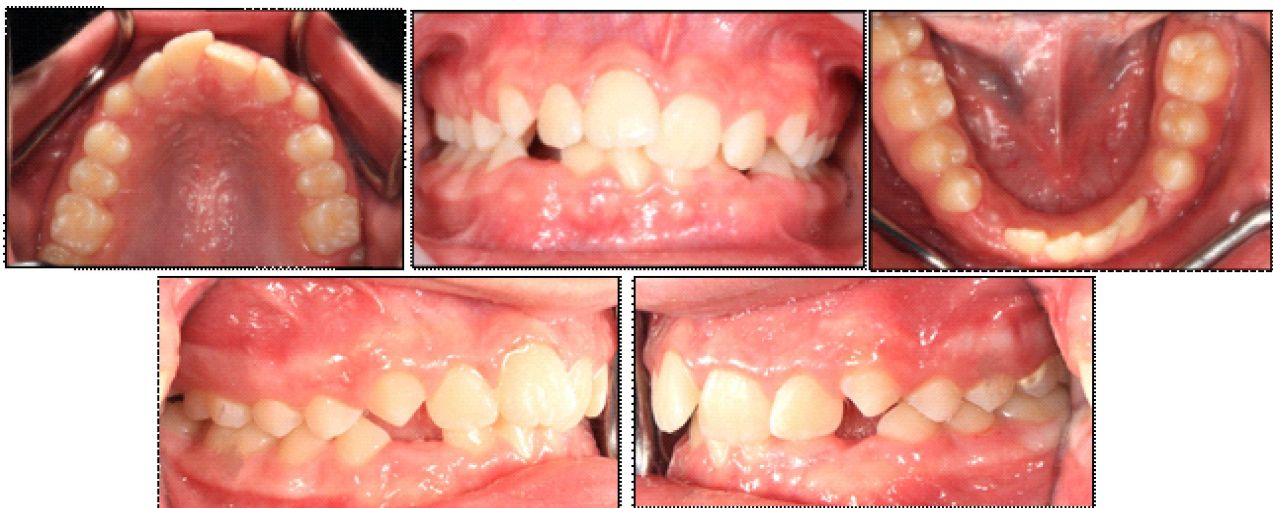

Fig 3. showing post-functional appliance therapy intra-oral views of patient

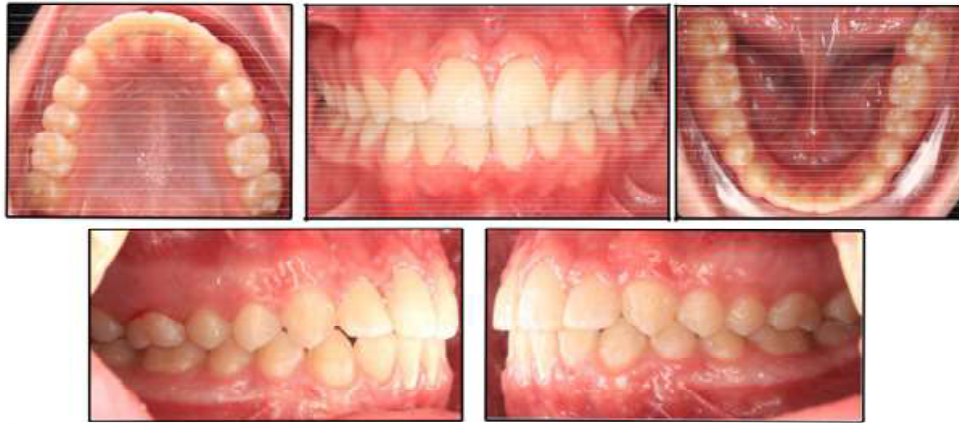

Fig 4. Showing post-treatment intra-oral pictures

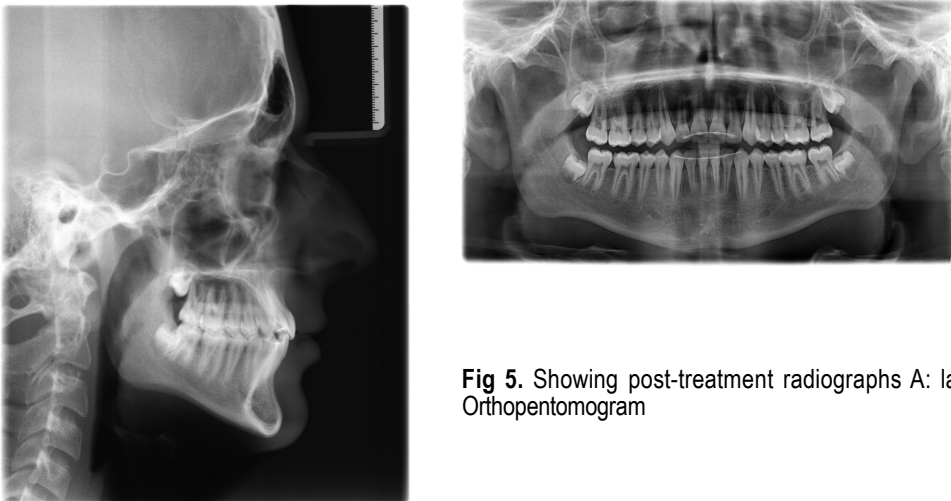


Fig 5. Showing post-treatment radiographs A: lateral cephalometric B: Orthopantomogram

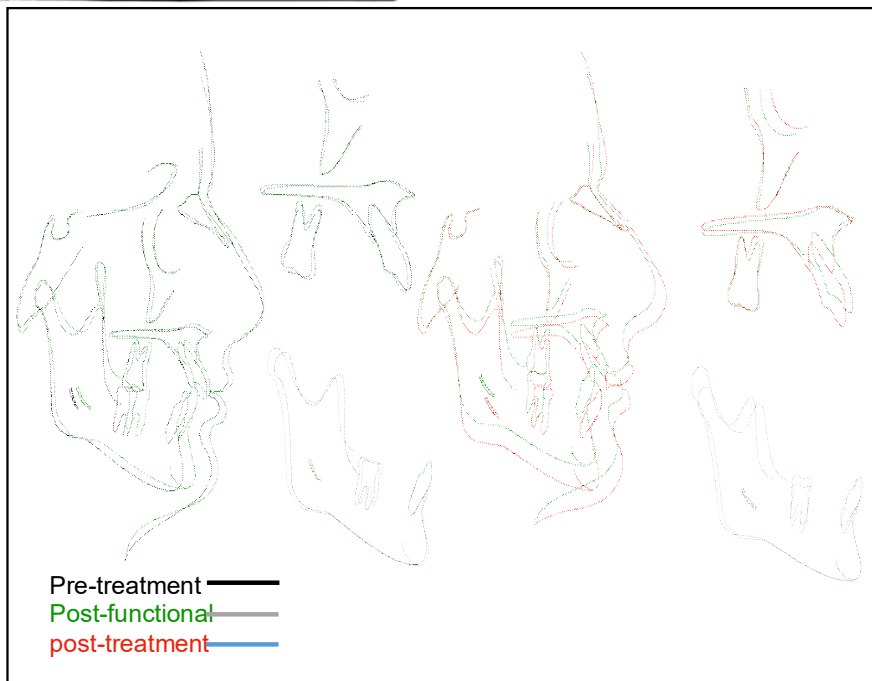


Fig 6. Showing cephalometric superimpositions showing outcome

The choice of functional appliances is reliant on many aspects which may be related to patient example oldness, amenableness, scientific influences e.g., partiality/ acquaintance and lab facilities<sup>9,10</sup>.

The patient must be instructed for follow up visits to check for retention appliance. The prognosis for stability is good provided that the patient complies with the retention regime. Patient was instructed to follow the instructions strictly.

### Conclusion

The quest of standards in orthodontics, facial equilibrium and synchronization are correspondingly vital in visual and functional perfection. The functional jaw orthopedics plays pivotal role through growth regulation through developmental ages of facial and dental progress. Although every patient responds variably according to their body response, through careful planning, observation and monitoring of patients, optimal results of functional jaw orthopaedics can be achieved.

### References

1. Jena AK, Duggal R, Parkash H. Skeletal and dentoalveolar effects of Twin-block and bionator appliances in the treatment of Class II malocclusion: a comparative study. *Am J Orthod Dentofacial Orthop* 2006;130:594-602. [doi: 10.1016/j.ajodo.2005.02.025]
2. Yezdani A. Two-Phase Therapy of a Severe Skeletal Class II Malocclusion [Online]. *Biomedical and Pharmacology Journal* 2015 Oct 25;8:425-32. Available from: <https://biomedpharmajournal.org/vol8octoberspledition/two-phase-therapy-of-a-severe-skeletal-class-ii-malocclusion/>. Accessed on: 29th September 2020. [doi:<https://dx.doi.org/10.13005/bpj/716>]
3. Srivastava K, Tikku T, Khanna R, Maurya RP, Verma SL, Srivastava A. Fixed Twin Block-A Clinically Effective Appliance in Growth Modification of Class II Malocclusion-Case Presentation [Online]. *J Adv Med Dent Scie Res* 2020;8:119-26. Available from: <http://jamdsr.com/uploadfiles/33Fixedtwinblockvol8issue2pp119-126.20200311044109.pdf>. Accessed on: 29th September 2020.
4. Clark WJ. The Twin Block technique. A functional orthopaedic appliance system. *Am J Orthod Dentofac Orthop* 1988;93:1-18.[doi: 10.1016/0889-5406(88)90188-6.]
5. Azeem M, Haq AU, Hamid WU, Hayat MB, Khan DI, Ahmed A, et al. Efficiency of class III malocclusion treatment with 2-premolar extraction and molar distalization protocols. *Int Orthod* 2018;16:665-75.[doi: 10.1016/j.ortho.2018.09.007.]
6. Ong HB, Woods MG. An occlusal and cephalometric analysis of maxillary first and second premolar extraction effects. *Angle Orthod* 2001;71(2):90-102. [doi: 10.1043/0000-3219(2001)071<0090:AOACAO>2.0.CO;2.]
7. Patel P, Shanthraj R, Garg N, Vallakati A. Skeletal Class II division 1 malocclusion treated with twin-block appliance [Online]. *Int J Orthod Rehabil* 2017;8:31. Available from:<http://www.orthodrehab.org/article.asp?issn=2349-5243;year=2017;volume=8;issue=1;spage=31;epage=37;aulast=Patel>. Accessed on: 29th September 2020.
8. Zymperdikas VF, Koretsi V, Papageorgiou SN, Papadopoulos MA. Treatment effects of fixed functional appliances in patients with Class II malocclusion: a systematic review and meta-analysis. *Eur Orthod* 2016;38:113-26. [doi: 10.1093/ejo/cjv034.]
9. Lee KY, Park JH, Tai K, Chae JM. Treatment with Twin-block appliance followed by fixed appliance therapy in a growing Class II patient. *Am J Orthod Dento facial Orthop* 2016;150:847-63. [doi: 10.1016/j.ajodo.2015.10.033.]