

Frequency of Anatomical Variations and Congenital Anomalies in Pancreatobiliary Tract through Magnetic Resonance Cholangiopancreatography

Imran Ishaque¹, Naveed Ali Siddiqui², Mahveen³, Jay Kreshan⁴, Sara⁵, Amber Ilyas⁶

Abstract

Objective: To determine the frequency of anatomical variations and congenital anomalies of pancreatobiliary tract in adults through the Magnetic Resonance Cholangiopancreatography (MRCP).

Methods: This cross-sectional observational study was done on patients suspected to have pancreatobiliary disease referred to MRI unit. MRCP was performed on a 1.5 Tesla in MR unit, using phased-array coil for signal detection. Heavily T2 weighted images were obtained with SSF-SE technique. Axial and coronal source images and reformatted images were evaluated together for the possibility of any anomaly and variation in pancreatobiliary tract. Analysis was done by SPSS version 20.

Results: Total no of 377 patients included in this study. The patients presented with epigastric pain, obstructive jaundice, pancreatitis and post-cholecystectomy epigastric pain and jaundice. MRCP was performed on these patients to examine the pancreatobiliary tract. In this study, 52% were females and 48% were males. The variations and anomalies were found in 24.93 and 75.07% had normal anatomy of pancreatobiliary tract. The most observed frequency was low insertion of cystic duct and least observed frequency was duct of Santorini. High insertion of cystic duct, absent gallbladder and aberrant hepatic ducts were not found in this study.

Conclusion: Majority of the patients in this study were found to be free from pancreatobiliary disease. It is important to clarify the anatomy of the pancreatobiliary tract by preoperative evaluation. Congenital anomalies and anatomical variation in pancreatobiliary tract present a complex spectrum, which are worthy of alteration in both the clinical and surgical setting and are readily identified by MRCP.

Keywords: Pancreas, biliary tract, magnetic resonance imaging.

IRB: Approved by Institutional Review Board of Dow University of Health Sciences. Dated 29th May 2012. Ref No. IRB-330/DUHS-12

Citation: Ishaq I, Siddiqui NA, Mahveen, Kreshan J, Sara, Ilyas A, Frequency of Anatomical Variations and Congenital Anomalies in Pancreatobiliary Tract Through Magnetic Resonance Cholangiopancreatography [Online]. *Annals ASH & KMDC* 2020;25.

(ASH & KMDC 25(4):204;2020)

Introduction

Deleterious consequences during peri-operative pancreaticobiliary surgery include bile duct injuries and their risk increases with the presence of anatomical variations. Therefore, pre-operative evaluation and identifying the anatomic variation or anomaly is useful for avoiding injury during surgery.

Surgeon's expertise is vital in detecting anatomical variation or congenital anomaly during surgery. It has been reported that among general population, 57.7% show normal pancreaticobiliary tract anatomy while from the remainder 42.3%, 41% show variation and 1.3% show anomaly in pancreaticobiliary tract¹⁻³. Studies show female predominance in variation and anomaly in comparison to male, probably as a consequence of different embryological development². The reported variation is seen higher among Asians in comparison to USA and Europe⁴. For reductions in post-operative complication, as strong background knowledge of pancreaticobiliary tract anatomy is pivotal, similarly a strong knowledge of anatomical variation and anomaly is also vital³⁻⁴. The variations in anatomy

¹Department of Anatomy,

²Department of Biochemistry,

³Department of Pathology,

⁴Department of Community of Health Medicine, United Medical and Dental College

⁵Department of Anatomy, Dow University of Health Sciences

⁶Department of Anatomy, Sindh Medical College

Correspondence: Dr. Imran Ishaque

Department of Anatomy, United Medical & Dental College

Email: dr_imran_ishaq@yahoo.com

Date of Submission: 21st July 2020

Date of Acceptance: 13th March 2021

and anomalies of pancreaticobiliary tract are usually asymptomatic in childhood and either diagnosed as an incidental finding or in adulthood. The sign and symptoms seen are pain in the abdomen, nausea and vomiting which might be because of recurrent pancreatitis or obstructed gastric outlet due to pancreatic variant (congenital) or pancreatic duct system⁵.

Surgeon's knowledge of normal pancreaticobiliary anatomy with its abnormalities is useful for identifying and differentiating them between structures involved during surgery. Lack of proper knowledge may lead to trauma, biliary leak, division or ligation of the major bile duct⁶.

During pancreaticobiliary surgery, bile duct trauma is common in both laparoscopy or in open (laparotomy) technique. Present data is inconclusive regarding incidence of injury to bile duct; however, a rough estimation shows 1 in a 1,000 cases⁷. Injuries to bile duct can have life threatening complications, and are usually seen during cholecystectomies, especially laparoscopic in comparison to open technique, probably because of distortion in anatomy, variations in anatomy or pancreaticobiliary tract anomalies. In cholecystectomy, injury to bile duct is seen in 0.3 % to 0.62 % of patients and this figure is observed in patients having anatomic variations or anomalies⁸. In order to prevent peri-operative damage to biliary tract, it is vital to have pre-operative investigations for anatomic variation and / or anomalies in the patients undergoing surgery. Multiple radiological procedures can be carried out to detect pancreatobiliary tract abnormalities. These include the conventional cholangiography, ultrasonography (U/S), biliary scintigraphy, endoscopic retrograde C cholangio-pancreatogram (ERCP) and percutaneous trans-hepatic cholangiogram (PTC)⁹.

In order to examine the anatomy of pancreaticobiliary and hepatobiliary tract, magnetic resonance imaging (MRI) of a special type is used, known as MRCP. This MRI provides information about the physiology as well as pathology of pancreaticobiliary and hepatobiliary system which

aids surgeons throughout the surgical procedure, to diagnose and treat the conditions accordingly. More importantly, MRCP is non-invasive. Assessing patency of pancreaticobiliary tract is of prime importance as patients undergoing pancreaticobiliary tract surgery commonly tend to have post-operative complications. Therefore, using the non-invasiveness methodology of MRCP, it has widely gained popularity for identifying ductal system in pancreaticobiliary tract. Through MRCP, clear plus accurate information regarding anatomical variations in bile ducts and anomalies within pancreaticobiliary tract helps to diagnose various types of disorders present in pancreaticobiliary system¹⁰. Examination through magnetic resonance (MR) is done on a 1.5 TESLA system (Siemens, Avanto, Erlangen and Signa). MRCP is an advanced method of testing compared to other techniques. Software mostly use is single shot fast spin echo (SSFSE) and T2 weighed images or single-section and multi-section by torso array coil. Pancreaticobiliary tract visibility is seen in coronal section whereas pancreatic duct and bile duct is seen in axial section. All sequences are acquired in a single breath-hold after 4-6 hours of fasting, for promoting filling of gallbladder. Whole procedure takes about 20 minutes¹¹. The rationale of the study will prove to be a useful addition to the research data of our country benefiting for clinical health professionals and decreasing the incidence of surgical complications during the procedure and the aim of the study to evaluate the existing congenital anomalies and anatomical variations in patients with pancreatobiliary tract disease using MRCP in adults.

Patients and Method

This cross-sectional multi-center study using non-probability convenient sampling technique was done at radiology department DUHS at Ojha and AKUH. After ethical approval and written informed consent was taken, 377 pancreaticobiliary tract disease patients were included in the study from radiology department in eight months. Inclusion criteria consisted of patients of either gender diagnosed as a case of pancreaticobiliary disease on ultrasonog-

raphy and patients having epigastric pain, obstructive jaundice, pancreatitis and post cholecystectomy epigastric pain and jaundice, post pubertal patients and MRCP images having clear anatomic views. Patients undergoing MRCP but images not being optimal on technical grounds, dementia patients, claustrophobic patients, patients unable to hold breath for 30 seconds or more, non MRI compatible pacemaker patients or patients with implants and mechanical prosthesis were excluded from the study.

Booking of patients was done before examining them. Prior to examination, patients were advised to have a 4-6 hour fasting state. Throughout the examination, loose and comfortable clothing gowns were given to the patients by the hospital. Each patient was explained about the procedure and written and informed consent sought. Machine's tunnel, sound of the machine and exercise for breath holding were all explained. In order to communicate with technologist, call bell was given to each patient and 350-500ml pineapple juice was provided 20 minutes prior to examination. Use of pineapple juice was done as a negative oral contrast material before examination. MRCP performed in Magnetic Resonance Image (MRI) unit on MRI scanner and images obtained using 1.5 TESLA (Magnetom, Vision, Erlangen, Siemens and Germany). The images were obtained on 1.5 TESLA by Siemens. The MRI scanner consisted of tunnel around 1.5-meter-long surrounded by large circular magnet. The patient lied on a couch with a slider into the scanner. A receiving device was placed behind, around or part of the body that was being examined. It helps in detecting tiny radio signals emitted from patient's body. Patient was still and silent when each image was taken. The whole process was around 15 - 20 minutes. Radiographer and participant were in control room next to the scanner and observed the procedure using a monitor. Open Epi website was used to calculate the sample size keeping 43% prevalence 12 of anatomical variations and congenital anomalies. $P < 0.05$, 5% margin of error and 95% confidence interval used to calculate the sample size which was

377. The data analysis was conducted by using SPSS versions 20. Since it was a qualitative data, the prevalence was measured in percentages. Prevalence of variations and anomalies in pancreaticobiliary tract were calculated at 95% confidence interval. The frequencies of parameters were statistically analysed by using binomial test. $P < 0.001$ was considered statistically significant. Frequencies or percentages were shown through bar graphs and tables.

Results

All 377 patients complained of epigastric pain, obstructive jaundice, pancreatitis and post cholecystectomy epigastric pain and jaundice. MRCP was done on these patients for examining pancreatobiliary tract. From 377 patients of the study, 52% are female and 48% were male. The variations and anomalies were found in 24.93% and 75.07% had normal pancreatobiliary tract anatomy Figure 1. The most observed frequency was low insertion of cystic duct and least observed frequency was duct of Santorini. High insertion of cystic duct, absent gallbladder and aberrant hepatic ducts were not found in this study. The mean age was $48 \pm$ SD years. The variation and anomalies were found in 94 patients and the frequency was 24.93%. Pancreas divisum was present in 21 patients with the frequency of 5.6%, duct of Santorini was seen in 3 patients with the frequency of 0.8%, pancreatic cyst was present in 17 patients with the frequency of 4.5%, low insertion of cystic duct was observed in 22 patients with the frequency of 5.8%, long cystic duct in 11 patients with the frequency of 2.9%, short cystic duct was seen in 05 patients (1.32%), choledochal cyst in 11 patients with the frequency of 2.9% and Phrygian cap in 6 patients with frequency of 1.6% Table 1. According to the observed variation and anomalies in the pancreato-biliary tract, pancreas divisum was found in 08 (4.4%) males and 13 (6.6%) females. Pseudo-pancreatic cyst was reported in 09 (5%) males and 08 (4.1%) females. Duct of Santorini was observed in 01 (0.6%) male and 02 (1%) female. A low ICD was seen in 13 (7.2%) males and 09 (4.6%) females.

Long CD was found in 05 (2.8%) males and females each while short CD was reported in 04 (2.2%) males and 01 (0.5%) females. Antero-posterior spiral CD was observed in 02 (1.1%) males and 04 (2%) females. Choledochocele was reported in 05 (2.8%) males and 06 (3.1%) females. Phrygian cap was seen in 02 (1.1%) male and 04 (2%) female. 01 (0.6%) male patient was found with an absent gall bladder

Table 1. Anatomical Variations and Anomalies in Pancreaticobiliary Tract

SNb	Anatomic Variation/ Anomalies	Frequency(n=94)	Percentage
1	Low insertion of cystic duct	22	58%
2	Pancreas divisum	21	56%
3	Pancreatic cyst	17	45%
4	Long cystic duct	11	29%
5	Choledochal cyst	11	29%
6	Phrygian cap	6	16%
7	Short cystic duct	5	13.2%
8	Pseudo pancreatic cyst	0	0
9	High insertion of cystic duct	0	0

Table 2. Anatomical Variations and Anomalies in Pancreatobiliary Tract According to Gender

Variation / Anomaly	Male (%) n=48	Female (%) n=52
Pancreas Divisum	08 (4.4%)	13 (6.6%)
Pseudo-pancreatic cyst	09 (5%)	08 (4.1%)
Duct of Santorini	01 (0.6%)	02 (1%)
ICD	LICD	13 (7.2%)
	HICD	09 (4.6 %)
CD	Long	05 (2.8%)
	Short	04 (2.2%)
Antero-Posterior Spiral CD	02 (1.1%)	04 (2%)
Choledochocele	05 (2.8%)	06 (3.1%)
Phrygian Cap	02 (1.1%)	04 (2%)
Absent Gallbladder	01 (0.6%)	0

Discussion

Disorders of the pancreaticobiliary tract are not uncommon amongst our population. It has been estimated that more anomalies are observed 1 cm³ around the extra-hepatic biliary system that is the region of cystic duct than any other body part.

Variations in anatomy lead to difficult operations, more specifically due to substantial anatomical changes of the process of disease itself. A wide range between incidence of congenital anomalies and anatomic variations are observed from as low as 0.58% to as high as 47.2%. Pin-point incidence of biliary system anomalies is unknown. Therefore, it is vital to avoid such biliary complications at the surgery, through thorough pre-operative workup, to know before hand and diagnose anomalies and anatomic variation in the pancreaticobiliary tract. Clinically, anatomical variations are mostly of no importance; however they might cause confusion at the time of surgery or during diagnostic examinations. Additionally, such variations could complicate procedure such as endoscopy or PTC, open as well as laparoscopic cholecystectomy, liver transplantations by causing iatrogenic trauma. Such anatomic variation mostly causes problems for surgeons, more often when diseases persist simultaneously. A lacking in identifying these variations properly might cause either division, injury of ligation of major bile ducts. For preventing such complications, a surgeon ought to have background knowledge of basic anatomy and variations regarding extra-hepatic biliary tract and its surgical implications¹³.

According to the results of this study, from 377 patients of pancreaticobiliary tract disease were 52% females and 48% males having 48 years of mean age. 75.07% of patients were observed to have a normal anatomy while 24.93% were found to have anomalies and anatomic variations. Most frequently reported variation in the present research was low insertion cystic duct that was 5.8% and least found frequency was pancreas duct / duct of Santorini variation which was 0.80%, Divisum of pancreas was 5.6%, 4.5% patients were of pancreatic cyst, 2.9% had long cystic duct, 1.32% had short cystic duct, 2.9% had choledochal cyst and 1.6% were found to have Phrygian cap. Another research done on 10,243 patients reported 39.5% patients had a varying in anatomy and anomaly of pancreaticobiliary tract. This is not in agreement to our research. In a research performed by Morgan et al reported that pancreas divisum was found in 5-

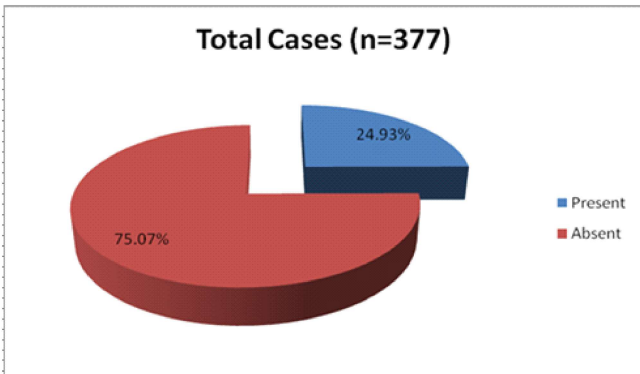


Fig 1. Shows the frequency of distribution of variations and anomalies in pancreatobiliary tract in adult patients through MRCP

10% of the patients and he concluded that it was an anomaly found congenitally. It was reported in studies that 15-20% of patients presented having unexplained and unrelenting pancreatitis. Pancreas divisum was reported in 21 (5.6%) of patients in the current study, that is in accordance to research, reporting frequency of pancreas divisum in their study to be 5.7% . On the contrary reported incidence to be higher, between 9.3% to 10.8%. Studies show that pancreas divisum is an anomaly more commonly seen among Western population in comparison to Asian population. With regards to researches done on accessory pancreatic duct [APD] patency, its incidence has been reported varying in-between 12% to 82%¹⁴.

According to studies by different researchers, the patency of APD had been reported from 12% - 82%. Dorsal pancreatic bud's main drainage is through APD in embryological life which enters duodenum at minor duodenal papilla. The function of APD's patency is for functioning as a secondary drainage system for main pancreatic duct [MPD] thereby preventing pancreatitis. APD was the least common pancreatic variation found in this study, having a frequency of 0.80%. This was substantially low in comparison to studies done by Kamisawa et al from 1989-2003 in Japan who reported 43% patent APD out of 291 control¹⁵. Our study reported an incidence of pancreatic cysts among 17 patients (4.5%) which is on the lower side of above incidences. Although it is reported that both genders are equally prone to pancreatic cyst development,

some have reported male predominance in comparison with females. Calot's triangle, an area where 90% of anomaly and variation relating to bile duct are found and where failure to identify them could cause surgical trauma and leaking of bile that might in turn cause substantial rises in morbidity and mortality¹⁶. A study reported that among 10.6% of patients, long cystic duct was seen parallel, related to extra-hepatic bile duct about 1.5 cm to about 9.5 cm whereas shorter cystic duct was only reported to be 5 mm in measurement¹⁷. In the present research, most reported variation was observed among 22 patients (5.8% of frequency) that were at low insertion of cystic duct. However another study also reported an incidence of low inserting cystic duct at about 7.4% and 11% respectively, both the frequencies not being in line with the reported incidence in our study¹⁸. In our research a shorter cystic duct was reported in only 05 patients having an incidence of 1.32% while a longer cystic duct was observed in 11 patients with an incidence of 2.9% that is comparable to studies done by Khan AS¹⁹. The choledochal cysts may be found in infants, children or above ages of 20 years and 20% of the population might be diagnosed with this disease some point in their life. Exact causative agent of choledochal cysts aren't known; however, it has been suggested to be possibly due to anomalous pancreatobiliary junction (APBJ) which leads to pancreatic juice reflux in towards common bile duct. Our research showed a 2.9% of choledochal cyst incidence rate among the total of 377 patients of the study. Among the 2.9%, more females in comparison to males were found to have the cysts, however all the patients presented with complaints of pain in the upper abdomen²⁰.

They may also have pancreatitis or gallbladder stones. Our findings were in comparison to a research carried out which reported 1.1% incidence rate among 356 patients. The incidences rates of choledochal cyst among the Western population are relatively low when compared to that of Asian population. Estimation on the prevalence rate among the West population has varied from 1 in 100,000 to 1 in 150,000. In Asian countries, there

is prevalence of 1 in 1000 and from them around 2/3 cases are found in Japan only, while 1 in 13,500 individuals residing in US and 1 in 15,000 among Australians have reported such incidences. Exact causative agents of preponderance amongst Asians are yet to be known. With regards to the commonly encountered anomalies of the biliary tract, the usually observed anomaly is folded gall bladder known as a Phrygian cap malformation which was first reported by Boyden and observed that its resemblance was to a Bonnet worn by Phrygians that lived in Asia in 12th century. The reported incidence of Phrygian cap in this study was found to be 1.6% from 377 patients which is in line with a research carried out by Rajguru J et al, which reported an incidence of 3.3%²¹.

This study was a multi-centered study done to decrease bias and gather data from more than one center to make it more authentic; however the study might not be immune from observer and selection bias. Surgical expertise also played an important role in the study. The study did not include histopathological diagnosis of the variation / anomalies found. Further studies should help in diagnosing pancreatobiliary variation or anomalies as a diagnostic modality and not an incidental finding.

Conclusion

According to the study results, it is important to clarify the anatomy of the pancreatobiliary tract by preoperative evaluation. Congenital anomalies and anatomical variations in pancreatobiliary tract present a complex spectrum, which are worthy of alteration in both the clinical and surgical setting and are readily identified by MRCP.

References

- De Filippo M, Calabrese M, Quinto S, Rastelli A, Bertellini, R, Martora R, et al. Congenital anomalies and variations of the bile and pancreatic ducts: magnetic resonance cholangiopancreatography findings, epidemiology and clinical significance. *Radiol med* 2008;113:841-859. [DOI: 10.1007/s11547-008-0298-x]
- Cucchetti A, Peri E, Cescon M, Zanello M, Ercolani G, Zanfi C, et al. Anatomic Variations of Intrahepatic Bile Ducts in a European Series and Meta-analysis of the Literature. *J Gastrointest Surg* 2011;15:623-630. [DOI: 10.1007/s11605-011-1447-4]
- Dimitriou I, Katsourakis A, Nikolaidou E, Nossios G. The Main Anatomical Variations of the Pancreatic Duct System: Review of the Literature and Its Importance in Surgical Practice. *J Clin Med Res* 2018; 10: 370-375. [DOI: 10.14740/jocmr3344w.]
- Turkvatan A, Erden A, Turkoglu MA, Yener O. Congenital variants and anomalies of the pancreas and pancreatic duct: imaging by magnetic resonance cholangiopancreatography and multidetector computed tomography. *Korean J Radiol* 2013;14:905-913. [DOI: 10.3348/kjr.2013.14.6.905.]
- Adibelli ZH, Adatepe M, Imamoglu C, Esen OS, Erkan N, Yildirim M. Anatomic variations of the pancreatic duct and their relevance with the Cambridge classification system: MRCP findings of 1158 consecutive patients. *Radiol Oncol* 2016;50:370-377. [DOI: 10.1515/raon-2016-0041.]
- Kostakis ID, Feretis T, Stamopoulos P, Garoufalas Z, Dimitroulis D, Kykalos S, et al. A rare anatomical variation of the biliary tree. *J Surg Case Rep* 2017;2017:rjx087 [DOI: 10.1093/jscr/rjx087.]
- Chaib E, Kanas AF, Galvão FH, D'Albuquerque LA. Bile duct confluence: anatomic variations and its classification. *Surg Radiol Anat* 2014;36:105-9. [DOI: 10.1007/s00276-013-1157-6]
- Deka P, Islam M, Jindal D, Kumar N, Arora A, Negi SS. Analysis of biliary anatomy according to different classification systems. *Indian J Gastroenterol* 2014;33:23-30. [DOI: 10.1007/s12664-013-0371-9]
- Griffin N, Charles-Edwards G, Grant L. Magnetic resonance cholangiopancreatography: the ABC of MRCP. *Insights Imaging* 2012;3:11-21. [DOI: 10.1007/s13244-011-0129-9]
- Palmucci S, Roccasalva F, Piccoli M, Fuccio Sanza G, Valerio Foti P, Ragozzino A, et al. Contrast-Enhanced Magnetic Resonance Cholangiography: Practical Tips and Clinical Indications for Biliary Disease Management. *Gastroenterol Res Pract* 2017;2017: 2403012. [DOI: 10.1155/2017/2403012]
- Petrillo M, Ierardi AM, Tofanelli L, Maresca D, Angileri A, Patella F, et al. Gd-EOB-DTP-enhanced MRCP in the preoperative percutaneous management of intra and extrahepatic biliary leakages: does it matter? *Gland Surg* 2019;8: 174-183. [DOI: 10.21037/gs.2019.03.09]
- Dean AG, Sullivan KM, Soe MM. *OpenEpi: Open Source Epidemiologic Statistics for Public Health, Version 3.01*. [Online] 2013 [Cited 2011 May 11].

- Available from URL:https://www.openepi.com/Menu/OE_Menu.htm
13. Ishaque I, Ilyas A, Khan O, Kazmi QH, Ladak AH and Rafay A. Role of magnetic resonance cholangiopancreatography (MRCP) in leading anatomical variations in pancreatic duct. JPMA 2020;70:472-475 [doi: 10.5455/JPMA.15767]
 14. Lin TK, Abu-El-Haija M, Nathan JD, Palermo JP, Barth B, Bellin M, et al. Pancreas divisum in pediatric acute recurrent and chronic pancreatitis: report from INSPPIRE. J Clin Gastroenterol 2019;53:e232-38. [doi: 10.1097/MCG.0000000000001063]
 15. Wang T, Liu DQ, Wen XD, Zhang BY, Liu WH. Endoscopic dissection of refractory pancreatic duct stricture via accessory pancreatic duct approach for concurrent treatment of anomalous pancreaticobiliary junction in aging patients. Clin Interv Aging 2019;14:557-563 [doi: 10.2147/CIA.S191055]
 16. Khan AS, Paracha SA, Shah Z, Tahir M, Wahab K. Anatomical variations of cystic duct encountered during open cholecystectomy [Online]. Khyber Med Univ J 2012;4:19-22. Available from: <http://www.kmu.edu.pk/article/view/8614>. Accessed on: 26th January 2021.
 17. Kim MH, Lim BC, Park HJ, Lee SK, Kim CD, Roe IH, et al. Korean J Gastrointest
 18. Buddingh KT, Morks AN, Hoedemaker HOTC, Blaauw CB, van Dam GM, Ploeg RJ, et al. Documenting correct assessment of biliary anatomy during laparoscopic cholecystectomy. Surg Endosc 2012;26: 79-85. [DOI:10.1007/s00464-011-1831-x]
 19. Jung-Ta K, Chung-Mou K, Yi-Chun C, Chi-Sin C, Chung-Huang K. Congenital anomaly of low insertion of cystic duct: Endoscopic retrograde cholangio-pancreatography findings and clinical significance. J Clin Gastroenterol 2011;45:626-29. [DOI: 10.1097/MCG.0b013e31821bf824]
 20. Talpur KA, Laghari AA, Yousfani SA, Malik AM, Memon AI, Khan SA. Anatomical variations and congenital anomalies of extra hepatic biliary system encountered during laparoscopic cholecystectomy. J Pak Med Assoc 2010;60:89-93.
 21. Hasan MM, Reza E, Khan MR, Laila SZ, Rahman F, Mamun MH. Anatomical and congenital anomalies of extra hepatic biliary system encountered during cholecystectomy. Mymensingh Med J 2013; 22:20-6.