

Pictorial Quiz

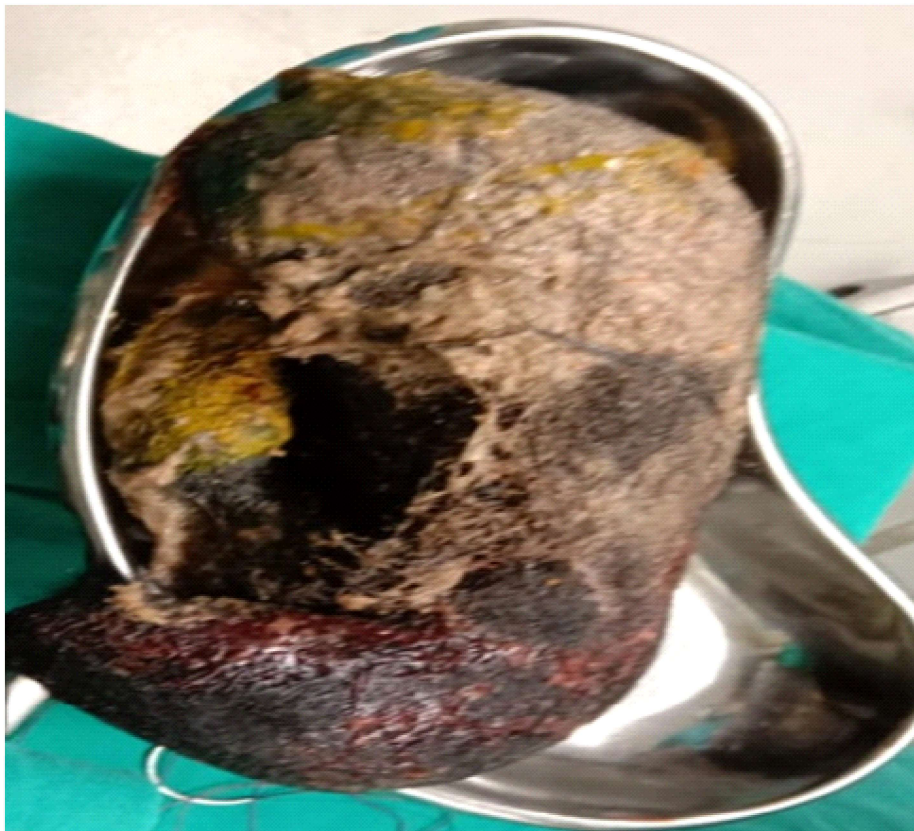
Fatima Iqbal¹, Muhammad Jamaluddin²

Case scenario

My patient 30 years of age G3P2 with 30 weeks of gestational amenorrhea came with complain of abdominal distension, relative constipation and multiple episodes of vomitings for 3 days. She had history of eating hairs for 3 years. On examination, abdomen was distended and tense overall.

Gutsounds inaudible. Digital rectal examination was unremarkable. X-ray Erect abdomen showed multiple air fluid levels. Attached below is the picture of operative finding.

What is your diagnosis?



^{1,2}Department of Surgery Unit II,
Abbasi Shaheed Hospital Karachi

Correspondence: Dr.Fatima Iqbal
Department of surgery unit II, Abbasi Shaheed Hospital
Email: drfatimaiqbal90@gmail.com

Answer on Page 102