

Pictorial Quiz

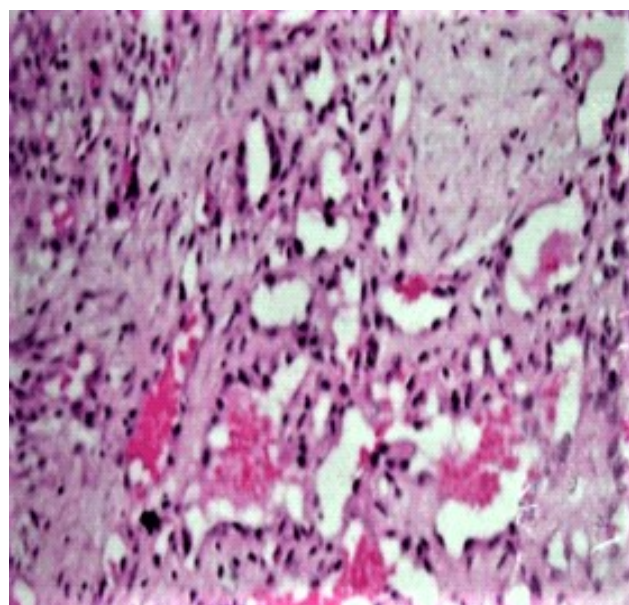
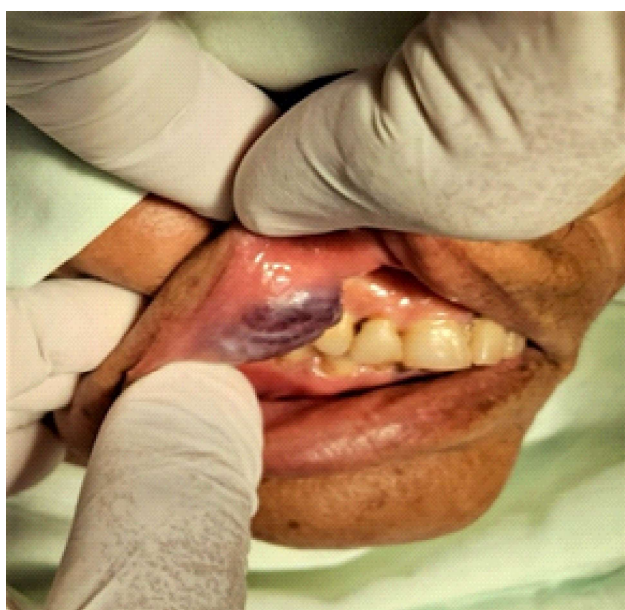
Ameema Javed¹, Syeda Baneen Rizvi²

Case scenario

A 64-years-old female patient presented to the oral maxillofacial department with a solitary growing exophytic, pedunculated lesion measuring 3x2 x1 cm on the right upper labial mucosa. The growth developed 8 months back and was slightly smaller than that at the time of presentation. The lesion was soft and edematous in consistency and tender on provocation.

The histopathology revealed stratified squamous epithelium with acanthosis and irregular downward proliferation of rete pegs. Immediate sub-epithelium showed dense infiltration by plasma cells, neutrophils, lymphocytes, and eosinophils. Multinucleated giant cells of varying size in a stroma composed of ovoid and spindle shaped fibroblasts and some dilated and congested blood vessels could be seen.

What is your diagnosis?



^{1,2}Department of Oral Maxillofacial Surgery,
Abbasi Shaheed Hospital and
Karachi Medical and Dental College

Correspondence: Ameema Javed
Department of Oral Maxillofacial Surgery,
Abbasi Shaheed Hospital and
Karachi Medical and Dental College
Email: ameema.javed.aj@gmail.com
Date of Submission:
Date of Acceptance:

Answer of Pictorial Quiz
Lobular Capillary Hemangioma