

Comparison of Intra Articular Platelet Rich Plasma with Corticosteroids in Patients with Temporomandibular Dysfunction syndrome

Sahar Usman¹, Sufyan Ahmed², Sana Iqbal³, Mirza Hamid Baig⁵, Ajeet Kumar⁶, Uzma Shamsi⁷

Abstract

Objective: To evaluate comparison of intra-articular injection of Platelet Rich Plasma (PRP) and corticosteroids in patients with Temporo Mandibular Joint Dysfunction syndrome.

Methods: This case-control study was conducted at Department of Oral Maxillofacial Surgery in a tertiary care hospital, Karachi. The inclusion criteria was patients with either gender aged from 25-50 years, previously diagnosed with TMJ dysfunction syndrome, not responding to conservative management. Patients with stage 3 & 4 TMD disease and uncontrolled comorbidities were excluded. After taking informed consent predesigned questionnaire was used to collect information from patients, about their socio demographic and lifestyle-related factors. Based on clinical and radiological data as well as the Research Diagnostic Criteria for Temporomandibular Disorders (RDC/TMD), a diagnosis of TMPDS was established. PRP was injected into the upper joint space in the PRP group and triamcinolone in other group. Follow-up was conducted after one-week, one month and third-month intervals. Respectively .Evaluation of reduction in symptoms was conducted using VAS pain scoring system and other parameters were measured in millimeters by an unassisted maximum incisal opening method using Vernier Caliper. Data was analysed using SPSS v. 21. P-value \geq 0.05 was considered significant.

Results: Total 16 (66.7 %) were females. Maximum age group that received treatment was 38 years i.e. 4 (16.7%). Mean age was 32.75 ± 5.01 years. It was evident that mouth opening increased significantly along with an increase in lateral protrusive movement from 6 mm to 7 mm. Joint tenderness was reduced up to 50%. Although joint clicks slightly increased from 58.3% to 62.5%. When comparing the PRP group to control group, pain score was significantly reduced (p-value: <0.001).

Conclusion: In patients with Temporo Mandibular Joint Dysfunction syndrome, it was discovered that intra-articular PRP injection was more successful in symptom reduction than corticosteroid injection.

Keywords: Temporo mandibular Disorder, Platelet Rich Plasma, Corticosteroid, Triamcinolone

IRB: Approved by the Ethical and Scientific Review Committee of Karachi Medical and Dental College. Ref# 033/19. Dated: 9th September 2020.

Citation: Usman S, Ahmed S, Iqbal S, Kashif M, Baig MH, Kumar A, Shamsi U. Comparison of Intra Articular Platelet Rich Plasma with Corticosteroids in Patients with Temporomandibular Dysfunction syndrome [Online]. Annals ASH & KMDC.

(ASH & KMDC 26(3):185-193;2023)

Introduction

A specialized fibrous tissue known as the retro-discal tissues, an articular disk, many ligaments, the mandible, a portion of the temporal bone, and numerous related muscles (muscles of mastication) constitute the temporomandibular joint (TMJ),

which is a syno-arthritis or complex joint¹. The TMJ is unique from the other joints of our body; that is, movement is possible in three dimensions, opening, and closing of the jaw causing translational movement in the joint space, lateral excursive movement of the jaw causing rotation of the head of the condyle and protrusive movement of the jaw is caused by gliding movement of the head of condyle². Temporomandibular dysfunction syndrome falls 3rd in frequency among orofacial disorders³. Although symptoms may be variable, common symptoms that usually patients present with are, pain in the mouth opening or difficulty in mouth opening and joint clicking and/or headaches. Clinical signs of TMD are limited mouth opening, Jaw

¹⁻³Department of Oral and Maxillofacial surgery, Abbasi Shaheed Hospital and Karachi Medical and Dental and College

⁴. Department of Oral Pathology, Karachi Medical and Dental College.

^{5,6} Department of Oral and Maxillofacial Surgery. Sir Syed College of Medical Science and Hospital

⁷Aga Khan University Hospital

Correspondence: Dr. Sana Iqbal
Department of Oral and Maxillofacial surgery,
Abbasi Shaheed Hospital and
Karachi Medical and Dental College
Email: s_taurian@hotmail.com

Date of Submission: 24th June 2023

Date of Acceptance: 30th November 2023

deviation, click or crepitus (audible/ on palpation) with mandibular movement, and tenderness at the origin of muscles of mastication. However, there is no standard treatment for reducing myofascial pain syndrome and many patients are refractive to conservative management⁴. Conservative treatment options for temporomandibular joint dysfunction pain syndrome include, medications, supportive physical therapy techniques, rehabilitation techniques, muscle training, fabrication of occlusal splints in different designs, and psychological support. If the conservative management fails to respond for 6 months follow-up then interventional procedures to the TMJ may initiate. Among the range of surgical procedures for TMJ, the most conservative surgical method used is Arthrocentesis with or without Arthroscopy.

This involves the injecting and lavage of different solutions at different intervals in the literature performed to give symptom relief. Out of those using Ringer's Lactate solution, or a mixed solution of local anesthetics and corticosteroids is one of the conventional methods of this procedure. Similarly, joint arthrocentesis is a longstanding established procedure used for larger joints in orthopedics^{1,5}. More recent approaches to promoting cartilage regeneration are being studied, such as growth factors that can start cellular division, development, and maturation. Previous studies have shown that platelets can secrete these growth factors (GFs), to name a few, platelet-derived growth factors A and B, transforming GF-b (TGF-b), insulin-like GF-I (IGF- I), epidermal GF, and endothelial cell GF are the ones responsible for stimulating newer cells formation, and differentiating that helps in the repair of the intra-articular environment. Consequently, a concentration of platelets rich in blood plasma is known as platelet-rich plasma (PRP). While the usual concentration of platelets in the blood is 200,000/ml, prior research has shown that the platelet count in platelet-rich plasma (PRP) can exceed 2 million/ml. Because PRP is a safe therapeutic option that can reduce pain and enhance functioning, it has also been utilized effectively in the treatment of degenerative pathological illnesses of the knee in recent times⁶. Autogenously, platelet-

rich plasma (PRP) concentrates were first developed in the late 20th century, but due to a lack of medical technology centrifugation techniques were not developed at that time, therefore, intra-articular use of this platelet concentrate was used in the 21st century⁷.

TMJ dysfunction syndrome is the most common subtype of TMJ disorders (TMD) affecting individuals at every socioeconomic and ethnic level⁸. PRP injections promote a healing environment inside the joint space, hence, facilitating earlier functional rehabilitation of joints. Additional advantages of PRP are cost-effectiveness as it's an autologous material, safety of the material, and no possibility of hypersensitivity to injected patient's plasma⁹.

A novel and potentially effective therapy for temporomandibular joint disease is platelet-rich plasma. PRP injections have been shown to be effective in reducing pain, improving mouth opening, and reducing joint clicking in patients with TMD. To validate the prolonged safety and effectiveness of PRP injections for TMD, further research is necessary.

The results of this study have given physicians important knowledge on the use of PRP in the management of TMD. The study's findings may aid medical professionals in treating TMD patients more effectively and achieving better patient outcomes. In particular, the results of this study may assist medical professionals in identifying patients who have the best chance of benefiting from platelet-rich plasma injections and in figuring out the ideal dosage and frequency of these treatments. All things considered, this study's conclusions may have a big influence on how TMD is treated clinically. It will also assist clinicians understand whether PRP can enhance patient outcomes by lowering side effects and improving patient management.

Methodology

It was a case-control study that was conducted at the Department of Oral and Maxillofacial Surgery from October 2020 to 2021 after the approval of the Ethical Review Board (Ref no. 033/19). The sampling technique used was simple random sampling. The inclusion criteria was all previously clinically diagnosed patients of TMJ dysfunction syndrome who did not respond to conservative management were included in this study. Patients with either gender (male & female) with ages ranging from 25-50 years without underlying comorbidities were included. Patients with stage 3 & 4 TMD disease and any co morbid were excluded. Written and informed consent was obtained from the patients and follow-up was ensured by regular contact with the patients. The Research Diagnostic Criteria for Temporomandibular Disorders (RDC/TMD) were used for establishing the diagnosis.

The assessment was done using detailed history and examination and investigations were ordered when necessary including labs and radiological assessments that are Orthopantomogram (OPG) X-ray and MRI scans to meet the inclusion criteria and to rule out any underlying connective tissue diseases, thrombocytopenia, anemia, neurological disorders or malignancies of the head and neck. A patient questionnaire was used to record the data obtained.

For comparison of two different treatment modalities, two patient Groups were formulated, Group I : Twelve TMD patients with diagnoses were included in Group I/Case Group, and each patient received a single intra-articular PRP injection. Group II: Twelve patients with TMD with diagnoses were included in Group II/Control Group, and they received a single intra-articular injection of corticosteroid, triamcinolone acetonide (kenacort® 40 mg/ml).

The identical anaesthetic method was used on both groups. Aseptic procedure was used in the preparation and draping of the patient. Five milliliters of the patient's blood were drawn into a sterile test tube that already contained half a milli-

liter of sodium citrate anticoagulant in order to make PRP. After inserting the tube into the centrifuge and centrifuging it for 15 minutes at 2100 rpm, the plasma was separated, transferred to a second plain test tube, and centrifuged once more for 10 minutes at 3500 rpm. The upper two-thirds of the plasma (PPP) was then discarded, and the bottom third (PRP) was injected using a 23-gauge needle. To block the auriculotemporal nerve, local anesthetic was subcutaneously administered at the location. For needle insertion into the upper joint space in Group I (case group), a Canthotragal line (Holmlund-Hellsing) and marking points A (10 mm from the middle of the tragus and 2 mm below the H-H line) and point B (20 mm from the middle of the tragus and 10 mm below the H-H line) were marked. A 23 gauge needle was used to gently inject 2 milliliters of prepared PRP while maintaining sterility. After the needles were taken out, the jaw was manually moved, and finger pressure was administered to the TMJ for a few minutes.

The control group II had identical aseptic patient preparation and draping, and 0.5 ml of Kenacort® (triamcinolone acetonide 40 mg/ml) was injected in the superior joint space using comparable markings. After the needle was removed, the patients in the case group received an identical finger pressure and jaw manipulation technique. To avoid discomfort and infection during the initial post-operative period, patients were recommended an oral soft diet, a pill called Augmentin® 1 gm twice a day for five days, and post-operative painkiller (acetaminophen) for three days. Patients were released with written instructions and contact information in case of an emergency. The Level of Pain by Visual Analog Scale (VAS), unaided maximum inter incisal opening (MIO), and the presence or absence of clicking in each group at the conclusion of the first week were used to record the clinical assessment of treatment outcomes. These measures were followed by monthly visits for three months. The patient was asked to open and close their mouth while the examiner checked for any clicking noises. Considering that pain and mouth opening are two of the most prevalent symptoms of

TMJ disease, the VAS score and MIO were utilized to quantify each of these symptoms. Because clicking is a typical finding in individuals with TMJ dysfunction, it was also evaluated.

Data was entered and SPSS version 23 was used for analysis. For the quantitative variables (VAS score and MIO), mean \pm standard deviation (SD) were determined. The post-stratification chi-square test was used to assess qualitative factors (the existence of clicking). Joint sounds, pain index scores, and maximal non-assisted (voluntary) mouth opening (MVMO) were among the variables that were compared between the two groups. The patient's age and gender were other variables. The mean VAS scores and MIO across the two groups were compared using an independent samples t-test as they were normally distributed and had equal variances.

Data was entered and SPSS version 23 was used for analysis. For numerical variables, mean and \pm standard deviation (SD) were computed. Maximum non-assisted (voluntary) mouth opening (MVMO), joint noises, and pain index scores were considered qualitative characteristics. Alongside the results, other factors including the patient's age and gender were assessed. A post-stratification chi-square test was used to maintain significance at a p-value of less than 0.05. The two groups were compared using the t-test.

Results

It has been observed that n=16 (66.7 %) were females among 24 patients. The maximum age group which receives treatment was 38 years and accounts for n=4 (16.7%) although the mean age was 32.75 \pm 5.01 years.

Table 1. Sociodemographic distribution of case (PRP) and control (Triamcinolone/steroid) groups

	PRP Column		TRI Column		*p value
	Count	n %	Count	n%	
Age cat	25-35	12 100.0	4	33.30%	<0.001
	36-40	0 0.0	8	66.70%	
Gender	Female	8 66.70%	8	66.70%	<0.001
	Male	4 33.30%	4	33.30%	

*fisher exact test

Table 2 shows the comparison of different measuring variables among different visits. The patients visited the clinic after a week and one month and 3 months interval. It was evident that mouth opening increased significantly up to 10mm, along with an increase in lateral protrusive movement from 6mm to 7mm. Joint tenderness was reduced up to 50%. Although joint clicks slightly increased from 58.3% to 62.5%. (Fig 1-5).

Table 2. Showing the frequency of different variables during the first and follow up visits

Number of Visit	Pain%(n)	Mouth Opening %(n)	Lateral Protrusive Movement%(n)	Joint Tenderness Yes	Joint Clicking Yes
First	Max Score 7=50(12)	28,29 mm 33.3 (8)	6 mm 37.5(9)	100(24)	58.3(14)
Second	Max Score 2=25(6)	35 mm 20.8(5)	7 mm= =54.2(13)	54.2(13)	70.8(17)
Third	Max Score 7=33.3(8)	37 mm= 20.8 (5)	7 mm= 45.8(11)	54.2 (13)	62.5(15)

Table 3 demonstrates test group descriptive statistics of patients on the first visit. To see the correlation between variables, Independent Samples T-test was applied. The Sig (2-tailed) p-value shows no significant difference in the pain score, mouth opening, lateral protrusive movement, and joint clicking of the PRP and triamcinolone group on the first visit.

At the follow-up visit, a significant distinction was noted between the PRP (case) group and the CS (control group) in terms of the VAS and MIO scores, indicating a significant decrease in pain. Additionally, the third visit demonstrates that a noteworthy distinction was seen between the PRP and triamcinolone groups in terms of pain score, mouth opening, lateral protrusive movement, and joint discomfort. Although no significant difference was found in joint clicking on the third visit.

Table 3. shows test Group Statistics of patients and the p-value of different variables on first, second, and third visit

Variables group	N	Mean	Std. Deviation	Std. Error	Mean	Sig. (2-tailed)
Group Statistics of patients on the first visit						
Pain	PRP	12	7.50	1.000	.289	0.052
	TRI	12	7.00	.603	.174	
Mouth Opening	PRP	12	29.08	.996	.288	0.568
	TRI	12	28.83	1.115	.322	
Lateral Protrusive Movement	PRP	12	5.50	.905	.261	0.088
	TRI	12	6.25	1.138	.329	
Joint Tenderness	PRP	12	1.00	.000 ^a	.000	0.076
	TRI	12	1.00	.000 ^a	.000	
Joint Clicking	PRP	12	.50	.522	.151	0.430
	TRI	12	.67	.492	.142	
Group Statistics of patients on the second visit						
Pain	PRP	12	2.83	1.193	.345	.000
	TRI	12	5.67	1.303	.376	
Mouth Opening	PRP	12	35.17	1.697	.490	.000
	TRI	12	29.08	1.505	.434	
Lateral Protrusive Movement	PRP	12	7.08	.515	.149	.001
	TRI	12	5.75	1.055	.305	
Joint Tenderness	PRP	12	.33	.492	.142	.042
	TRI	12	.75	.452	.131	
Joint Clicking	PRP	12	.50	.522	.151	.024
	TRI	12	.92	.289	.083	
Group Statistics of patients on the third visit						
Pain	PRP	12	1.67	.985	.284	.000
	TRI	12	7.00	.603	.174	
Mouth Opening	PRP	12	36.00	1.651	.477	.000
	TRI	12	27.25	2.261	.653	
Lateral Protrusive Movement	PRP	12	6.83	.835	.241	.020
	TRI	12	5.671	.371	.396	
Joint Tenderness	PRP	12	.08	.289	.083	.000
	TRI	12	.00	.000	.000	
Joint Clicking	PRP	12	.58	.515	.149	.689
	TRI	12	.67	.492	.142	

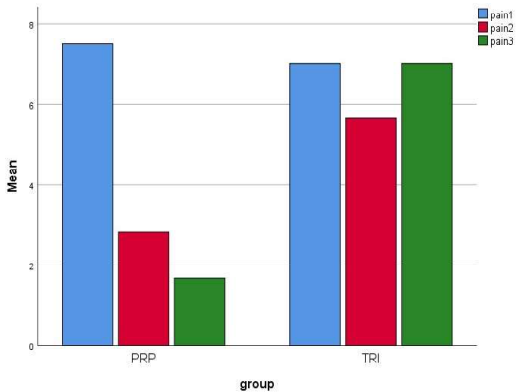


Fig 1. comparative analysis of pain scores among platelet rich plasma (PRP) and triamcinolone (TRI) group

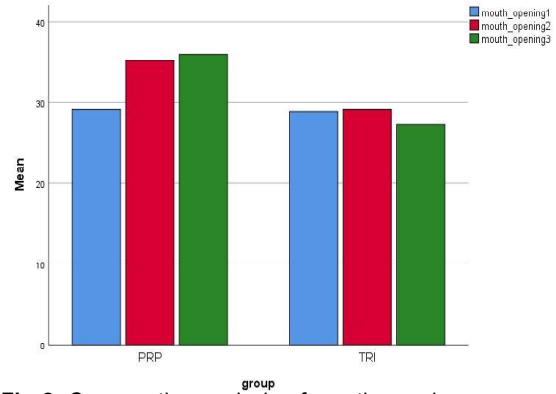


Fig 2. Comparative analysis of mouth opening among platelet rich plasma (PRP) and triamcinolone (TRI) group

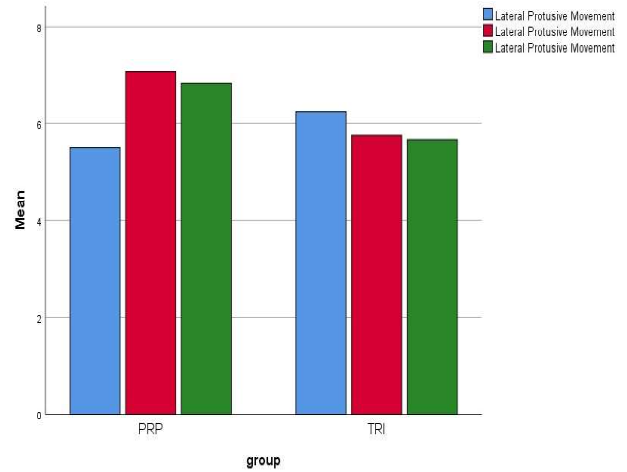


Fig 3. Comparative analysis of lateral protrusive movement among platelet rich plasma (PRP) and triamcinolone (TRI) group

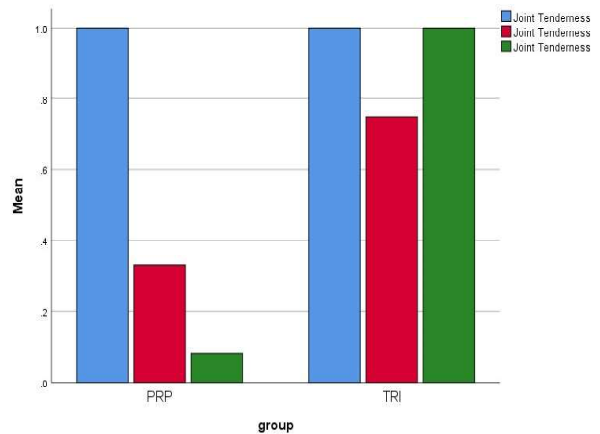


Fig 4. Comparative analysis of joint tenderness among platelet rich plasma (PRP) and triamcinolone (TRI) group

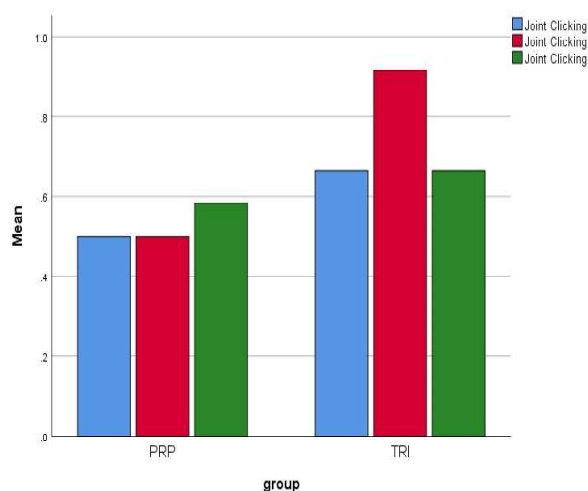


Fig 5. Comparative analysis of joint clicking among platelet rich plasma (PRP) and triamcinolone (TRI) group

Discussion

Temporomandibular joint disorder is a progressive disease that initiates with clinical symptoms of pain in the mouth opening, leading to trismus as described by the patients. This is clinically assessed by limited mouth opening, pain on the TMJ, and deviation on jaw opening, which in turn is caused by the retro discal connective tissues and the elevators and depressor muscles causing jaw movement, especially the lateral pterygoid muscle which is attached to the joint disc^{8,9}. The conservative treatment options begin with patient counseling, hot or cold applications, isometric jaw exercises, splint therapy, jaw physiotherapy, pharmacotherapy, ultra-sonographic therapy, and TENS therapy which should be considered the first-choice therapy in the initial stages of the disease because of fewer side effects for approximately 6 months¹⁰. However, if the disease or symptoms does not seem to improve then minimally invasive procedures play their part as the second line of treatment. Multiple investigations have revealed that women have clinical symptoms more frequently than men do, and being a woman may even increase the likelihood of developing TMD¹¹. This finding was consistent in our study and we found an increasing number of females compared to the male gender.

Other methods of treatment, such as intra-articular corticosteroids, morphine, hyaluronic acid, and long-acting anesthetic drugs, or a combination of them, have different success rates.¹² Similarly, different schedules have been tried in the past from single to multiple sessions. Our study used a single session of intra-articular PRP injection with a 3-month follow-up that showed improved symptoms in our patients. It can be assumed that multiple sessions of this therapy in future research may further improve TMD symptoms with better results compared to our study.

The platelet-rich plasma (PRP) utilized in our research is a combination of platelets and related growth factors that may have the ability to promote healing by promoting cell recruitment, differentiation, proliferation, and tissue remodeling^{13,14}. Corticosteroids inhibit prostaglandin synthesis, which is an important mediator of inflammation.

Produced from a patient's blood, platelet-rich plasma (PRP) is a concentration of platelets and the growth factors that proceed along with them. It has been used in clinical settings to treat soft-tissue oral ulcers, periodontal and oral surgical procedures, aesthetic plastic surgery, spinal fusion, and heart bypass surgery¹⁵⁻²⁰.

During the initial three months, there was a statistically significant decrease in the proportion of patients in each group who had clicking noises. This result was similar to that of Al-Delayme et al.²¹, but different from that of Hassan et al.¹, who utilized PRP and found no variation in joint sounds for the whole follow-up period. According to Moon et al.²², PRP did not work for clicking; it was only useful for managing restricted mouth opening and TMJ discomfort.

The application of platelet granules containing growth factors, or chemical mediators, into the milieu of the joint area is enhanced by PRP²³. The increased concentration of platelets and growth factors stimulates the early stage of the inflammatory response, which is characterized by the influx of neutrophils, monocytes, and macrop-

hages to the injury site²⁴. Fibroblasts proliferate, mediators and cytokines initiate the neovascularization processes, and more inflammatory cells are attracted in.

By suppressing the production of interleukin-1 from activated macrophages, local PRP treatment may also have an inhibitory effect on several pro-inflammatory cytokines that are harmful to the early phases of recovery. Despite the reparative cells' stimulatory actions, PRP promotes the growth of chondrocytes, increases the production of matrix molecules, and helps maintain the integrity of the chondral surface, all of which facilitate joint movement. PRP's analgesic effects have been highlighted in the literature, along with the cannabinoid receptors CB1 and CB2, which may be connected to these benefits. Emerging evidence suggests that PRP may be useful in the treatment of degenerative joint problems by reducing pain and stiffness in the joints ²⁵.

This is a pioneering investigation of its type to assess PRP's impact on both patients and controls. The primary drawback of our study was the small sample size. This operation is time-consuming, technique-sensitive, and might result in mild problems such as haemarthrosis, infection, or edema even in experienced clinicians. These are some of the limitations of this study.

More research with a bigger sample size, a longer follow-up time, and many treatment sessions is required to validate the results of this study and offer stronger proof of the long-term advantages of PRP injection for TMJ condition sufferers.

Conclusion

It has been concluded when treating patients with anterior disc displacement with decrease compared to the control group, it has been found that intra-articular PRP injection assists in pain reduction, enhances mouth opening, and slight increase in joint tenderness. Long-term research are necessary to explain the regenerative characteristics and stem cell activation capacity of PRP in

the TMJ, even though intra-articular PRP injection is a unique therapeutic technique that may be a promising option for the treatment of refractory TMD.

Conflict of Interest

Authors have no conflict of interest and no grant funding from any organization.

References

1. Hassan EF, Ali TM, Abdulla N. The clinical efficiency of platelet rich plasma in the treatment of temporomandibular joint disorders. *Alex Dent J* 2016;41(3): 226-31. [DOI: 10.21608/ADJALEXU.2016.58021]. Available from: https://adjalexu.journals.ekb.eg/article_58021.html. Accessed on 28th November 2023.
2. Rajapakse S, Ahmed N, Sidebottom AJ. Current thinking about the management of dysfunction of the temporomandibular joint: a review. *Br J Oral Maxillofac Surg*. 2017; 55(4): 351-6. [DOI: 10.1016/j.bjoms.2016.06.027]. Available from: [https://www.bjoms.com/article/S0266-4356\(16\)30236-4/fulltext](https://www.bjoms.com/article/S0266-4356(16)30236-4/fulltext). Accessed on 28th November 2023.
3. Schmid-Schwap M, Drahanowsky W, Bristela M, Kundi M, Piehlinger E, Robinson S. Diagnosis of temporomandibular dysfunction syndrome—image quality at 1.5 and 3.0 Tesla magnetic resonance imaging. *EurRadiol* 2009;19(5):1239-45. [DOI: 10.1007/s00330-008-1264-7]. Available from: <https://link.springer.com/article/10.1007/s00330-008-1264-7>. Accessed on 28th November 2023.
4. Vicente-Barrero M, Yu-Lu SL, Zhang B, Bocanegra-Perez S, Duran-Moreno D, Lopez-Marquez A, et al. The efficacy of acupuncture and decompression splints in the treatment of temporomandibular joint pain-dysfunction syndrome. *Med Oral Patol Oral Cir Bucal* 2012; 17(6): e1028-33. [DOI: 10.4317/medoral.17567]. Available from: <https://www.ncbi.nlm.nih.gov/pmc/articles/PMC3505698/>. Accessed on 28th November 2023.
5. Pihut M, Szuta M, Ferendiuk E, Zenczak-Wieckiewicz D. Evaluation of pain regression in patients with temporomandibular dysfunction treated by intra-articular platelet-rich plasma injections: a preliminary report. *Biomed Res Int*. 2014; 2014: 132369. [DOI: 10.1155/2014/132369]. Available from: <https://www.hindawi.com/journals/bmri/2014/132369/>. Accessed on 28th November 2023.

6. Kutuk N, Bas B, Soylu E, Gonen ZB, Yilmaz C, Balcioglu E, et al. Effect of platelet-rich plasma on fibrocartilage, cartilage, and bone repair in temporomandibular joint. *J Oral Maxillofac Surg.* 2014; 72(2): 277-84. [DOI: 10.1016/j.joms.2013.09.011]. Available from: [https://www.joms.org/article/S0278-2391\(13\)01198-1/fulltext](https://www.joms.org/article/S0278-2391(13)01198-1/fulltext). Accessed on 28th November 2023.
7. Araki J, Yamada Y, Omoto K, Nakasa T, Kato S, Morishita T. Optimized protocol for platelet-rich plasma preparation using double centrifugation for cell therapy in regenerative medicine. *J Clin Oncol* 2014;9(1):e85859. [DOI: 10.1200/JCO.2015.63.3826]. Available from: <https://pubmed.ncbi.nlm.nih.gov/26668349/>. Accessed on 28th November 2023.
8. Chandra, Lokesh, Goyal, Manoj, Srivastava, Dhirendra. Minimally invasive intraarticular platelet rich plasma injection for refractory temporomandibular joint dysfunction syndrome in comparison to arthrocentesis. *J Family Med Prim Care* 2021;10(1):254-258.[DOI: 10.4103/jfmpc.jfmpc_1633_20]. Available from: <https://www.ncbi.nlm.nih.gov/pmc/articles/PMC8132812/>. Accessed on 28th November 2023.
9. Wright EF, North SL. Management and treatment of temporomandibular disorders: A clinical perspective *J Man Manip Ther.* 2009; 17: 247–54. [DOI: 10.1179/106698109791352184]. Available from: <https://pubmed.ncbi.nlm.nih.gov/20140156/>. Accessed on 28th November 2023.
10. Gupta S, Sharma AK, Purohit J, Goyal R, Malviya Y, Jain S. Comparison between intra articular platelet-rich plasma injection versus hydrocortisone with local anesthetic injections in temporomandibular disorders: A double-blind study. *Int J Maxillofac Surg.* 2018; 9: 205–8. [DOI: 10.4103/njms.NJMS_69_16]. Available from: <https://www.lww.com/pages/default.aspx>. Accessed on 28th November 2023.
11. GökçeKutuk S, Gökçe G, Arslan M, Özkan Y, Kütük M, Kursat AO (2019) Clinical and radiological comparison of effects of platelet-rich plasma, hyaluronic acid, and corticosteroid injections on temporomandibular joint osteoarthritis. *J Craniofac Surg* 30(4):1144–1148. [DOI: 10.1097/SCS.0000000000005211]. Available from: https://journals.lww.com/jcraniofacialsurgery/abstract/2019/06000/clinical_and_radiological_comparison_of_effects_of.42.aspx. Accessed on 28th November 2023.
12. Guarda-Nardini L, Manfredini D, Ferronato G (2008) Arthrocentesis of the temporomandibular joint: a proposal for a single-needle technique. *Oral Surg Oral Med Oral Pathol Oral Radiol Endod* 106(4):483-6. [DOI: 10.1016/j.tripleo.2007.12.006]. Available from: [https://www.oooojournal.net/article/S1079-2104\(07\)00922-5/fulltext](https://www.oooojournal.net/article/S1079-2104(07)00922-5/fulltext). Accessed on 28th November 2023.
13. Sousa BM, López-Valverde N, López-Valverde A et al (2020) Different treatments in patients with temporomandibular joint disorders: a comparative randomized study. *Medicina (Kaunas)* 56(3):113. [DOI: 10.3390/medicina56030113]. Available from: <https://www.mdpi.com/1648-9144/56/3/113>. Accessed on 28th November 2023.
14. Filardo G, Kon E, RoffiA, Di Matteo B, Merli ML, Marcacci M. Platelet rich plasma: Why intra-articular? A systematic review of preclinical studies and clinical evidence on PRP for joint degeneration. *Knee Surg Sports TraumatolArthrosc* 2015; 23: 2459-74. [DOI: 10.1007/s00167-013-2743-1]. Available from: <https://link.springer.com/article/10.1007/s00167-013-2743-1>. Accessed on 28th November 2023.
15. Metzler P, von Wilmsowsky C, Zimmermann R, Wilffang J, Schlegel KA. The effect of current used bone substitution materials and platelet-rich plasma on periosteal cells by ectopic site implantation: An in-vivo pilot study. *J Craniomaxillo fac Surg* 2012; 40: 409-15. [DOI: 10.1016/j.jcms.2011.07.012]. Available from: <https://www.sciencedirect.com/science/article/abs/pii/S1010518211001727?via%3Dihub>. Accessed on 28th November 2023.
16. Leissner O, Maulén-Yáñez M, Meeder-Bella W, León-Morales C, Vergara-Bruna E, González-Arriagada WA (2021) Assessment of mandibular kinematics values and their relevance for the diagnosis of temporomandibular joint disorders. *J Dent Sci* 16(1):241–248. [DOI: 10.1016/j.jds.2020.05.015]. Available from: <https://www.ncbi.nlm.nih.gov/pmc/articles/PMC7770294/>. Accessed on 28th November 2023.
17. Iqbal S, Ahmed S, Ali Z, Kashif M, Aslam A. Evaluation of records of oral and maxillofacial surgery cases reported at abbasi shaheed hospital and Karachi medical and dental college, Pakistan. *The International Journal of Frontier Sciences.* 2020 Jan 1;4(1):47-51. [DOI: 10.37978/tijfs.v4i1.74]. Available from: <https://publie.frontierscienceassociates.com.pk/index.php/tijfs/article/view/74>. Accessed on 28th November 2023.
18. Mahmoud MA, Sharrawy E, Abdelhalim E, El Desouky GGE, Abdel Mabood ABA (2021) Evaluation of intra-articular injection of simvastatin versus hyaluronic acid in treatment of internal derangement of temporomandibular joint. *Dent Sci Updat* 2021;2(2):105–114. [DOI: 10.21608/DSU.2021.31287.1037]. Available from: https://dsu.journals.ekb.eg/article_192070.html. Accessed on 28th November 2023.
19. Welsh WJ. Autologous platelet gel: Clinical function and usage in plastic surgery. *Cosmet Dermatol* 2000;11:13. Available from: <http://www.perstat.com/plastic1.pdf>. Accessed on 28th November 2023.

20. Samiee A, Sabzerou D, Edalatpajouh F, Clark GT, Ram S. Temporomandibular joint injection with corticosteroid and local anesthetic for limited mouth opening. *J Oral Sci* 2011; 53: 321-5. [DOI: 10.2334/josnurd.53.321.]. Available from: <https://japanlinkcenter.org/JST.JSTAGE/josnurd/53.321?from=PubMed>. Accessed on 28th November 2023.
21. Al-Delayme RMA, Alnuamy SH, Hamid FT et al (2017) The efficacy of platelets rich plasma injection in the superior joint space of the temporomandibular joint guided by ultra sound in patients with non-reducing disk displacement. *J Maxillofac Oral Surg* 16(1):43–47. [DOI: 10.1007/s12663-016-0911-9]. Available from: <https://www.ncbi.nlm.nih.gov/pmc/articles/PMC5328864/>. Accessed on 28th November 2023.
22. Moon SY, Lee ST, Ryu JW. Ultrasound-guided platelet-rich plasma prolotherapy for temporomandibular disorders. *J Oral Med Pain* 2014;39(4):140–145. [DOI: 10.14476/jomp.2014.39.4.140]. Available from: https://www.researchgate.net/publication/276247027_Ultrasound-guided_Platelet-rich_Plasma_Prolotherapy_for_Temporomandibular_Disorders. Accessed on 28th November 2023.
23. Woodall J Jr, Tucci M, Mishra A, Asfour A, Benghuzzi H. Cellular effects of platelet rich plasmainterleukin1 release from PRP treated macrophages. *Biomed Sci Instrum* 2008; 44: 489-94. Available from: <https://pubmed.ncbi.nlm.nih.gov/19141963/>. Accessed on 28th November 2023.
24. Lin SL, Tsai CC, Wu SL, Ko SY, Chiang WF, Yang JW (2018) Effect of arthrocentesis plus platelet-rich plasma and platelet-rich plasma alone in the treatment of temporomandibular joint osteoarthritis: a retrospective matched cohort study (A STROBE-compliant article). *Medicine (Baltimore)* 97(16):e0477. [DOI: 10.1097/MD.00000000000010477]. Available from: https://journals.lww.com/md-journal/fulltext/2018/04200/effect_of_arthrocentesis_plus_platelet_rich_plasma.52.aspx. Accessed on 28th November 2023.



This open-access article distributed under the terms of the Creative Commons Attribution NonCommercial 4.0 License (CC BY-NC 4.0). To view a copy of this license, visit <http://creativecommons.org/licenses/by-nc/4.0/>